



Psoriatic arthritis and nail changes: Exploring the relationship



Matthew K. Sandre, HBMSc, BScN^a, Sherry Rohekar, BSc, MD, FRCPC, MSc (Clin Epi)^{b,*}

^a McMaster University School of Medicine, Hamilton, Ontario, Canada

^b Schulich School of Medicine, Division of Rheumatology, University of Western Ontario, St. Joseph's Hospital, 268 Grosvenor St, London, Ontario, Canada N6A 4V2

ARTICLE INFO

Keywords:

Psoriatic arthritis
Spondyloarthritis
Nail changes
Onychopathy
Psoriasis

ABSTRACT

Objective: Psoriatic arthritis (PsA) has a diverse range of clinical manifestations, both articular and extra-articular. Although the association of PsA with skin changes is well established, the relationship of PsA with psoriatic nail changes remains relatively unexplored.

Methods: This report reviews the current literature surrounding the association of PsA with nail changes. A review of the literature was completed using PubMed, MEDLINE, and EMBASE in September 2013, encompassing years 1964–2012.

Results: A total of 21 articles were reviewed. On average, 66% [standard deviation (SD) 17.7] of PsA patients had nail changes. The type of nail changes and their associations varied widely between studies.

Conclusions: Studies of nail changes in PsA are highly variable with a wide range of results. Given the variability of results that were observed in this review, our recommendations are that further large studies on nail changes in patients with PsA should be conducted.

© 2014 Elsevier Inc. All rights reserved.

Introduction

Psoriatic arthritis (PsA) is a seronegative spondyloarthritis associated with disease of the axial and peripheral joints, affecting upwards of 0.2% of the general population and 16% of the population living with psoriasis [1–4]. Clinical manifestations differ significantly between patients, with variations including joint, spine, and enthesal involvement, dactylitis, and new bone formation [3]. Extra-articular manifestations can also vary and may include cutaneous psoriasis, psoriatic nail changes, inflammatory bowel disease, and uveitis, with the cutaneous changes typically preceding the arthritis [5,6]. The great diversity in the presentation and progression of PsA adds to the challenge of its diagnosis.

Although skin changes are associated with PsA, psoriasis and PsA appear to have different inheritance patterns, with PsA having a stronger hereditary link than psoriasis itself [7,8]. Furthermore, human leukocyte antigen (HLA) typing seems to vary between the subtypes of PsA as well as between those PsA patients who progress differently along the disease course than others [9]. Multiple cytokines have been found in higher amounts than usual within the synovial tissue of PsA-affected joints, giving rise to the idea that multiple factors give rise to the joint damage associated

with this disease [10–13]. Receptor activator of nuclear factor kappa-B ligand (RANKL), a member of the tumor necrosis factor family, and interleukins 12 and 17 are three of the aforementioned cytokines that appear to be upregulated in PsA synovium [10–13]. Along with a downregulation of RANKLs opposing cytokine receptor, osteoprotegerin, these alterations have been shown to contribute to the increased bone resorption and disease in PsA [10–13].

To address the high variability of PsA, the current classification criteria, the Classification criteria for Psoriatic Arthritis (CASPAR) criteria (Table 1), include a combination of articular and extra-articular findings, along with personal and family history [3]. Although primarily including patients who had long-standing PsA (mean activity of 12.5 years), the original CASPAR study on this topic showed a high specificity and sensitivity (98.7% and 91.4%, respectively) [3]. A high sensitivity was later confirmed in early PsA patients [14]. However, it was noted that although the CASPAR criteria has good applicability in specialty rheumatology clinics, the ill-defined nature of inflammatory arthritis with regard to joint, spine, or enthesal disease may be problematic outside of these specialized clinics [14].

One of the CASPAR criteria, new bone formation in the juxtaarticular region on radiography, has lead researchers to look into new ways to discover such changes [3]. Recently, magnetic resonance imaging (MRI) and ultrasound imaging have become helpful tools in imaging the bone changes associated with PsA [15–23]. These imaging modalities may offer an explanation for

* Corresponding author. Tel.: +1 519 646 6242x2; fax: +1 519 646 6221.
E-mail address: Sherry.rohekar@sjhc.london.on.ca (S. Rohekar).

Table 1

The CASPAR (CIASsification criteria for Psoriatic Arthritis) criteria [3]

- A patient shall meet the CASPAR criteria if he or she has inflammatory articular disease (joint, spine, or enthesal) and 3/5 of the following criteria present (sensitivity 91.4% and specificity 98.7%) with current psoriasis counting as two and all others including personal and family history of psoriasis counting as one
- (1) *Psoriasis*
 - (a) Evidence of current psoriasis judged by a rheumatologist or a dermatologist
 - (b) Personal history of psoriasis from the patient or a qualified health care provider
 - (c) Family history of psoriasis in a first- or a second-degree relative
 - (2) *Psoriatic nail changes*—typically including onycholysis, pitting, and hyperkeratosis on current physical examination
 - (3) *Negative rheumatoid factor*—a negative test result for the presence of rheumatoid factor by any method except latex but preferably by enzyme-linked immunosorbent assay or nephelometry, according to the local laboratory reference range
 - (4) *Dactylitis*—current or a history of dactylitis (swelling of an entire digit) recorded by a rheumatologist
 - (5) *Radiographic evidence*—juxtaarticular new bone formation, appearing as ill-defined ossification near joint margins (but excluding osteophyte formation) on plain radiographs of the hand or the foot

why nail changes are associated with PsA. The use of new imaging techniques has led to the proposition that nail changes represent an enthesitis of the nail bed and matrix due to an association that exists between these structures and the nearby tendons and ligaments [16–24].

PsA nail changes are typically divided into those involving the nail matrix vs. those involving the nail bed [25]. When nail matrix disease is present, the typical findings include pitting, leukonychia,

nail plate crumbling, red spots on the lunula, and onychorrhexis (Fig. 1). This is in contrast to oil spot changes, onycholysis, subungual hyperkeratosis, and splinter hemorrhages, which are signs of nail bed disease (Fig. 2) [26–28].

Each of the different nail changes arise from unique processes within the nail complex. The loss of abnormal keratinocytes situated on the nail plate as it grows past the cuticle leaves divots or pits in its place [26,28,29]. Leukonychia are white discolorations

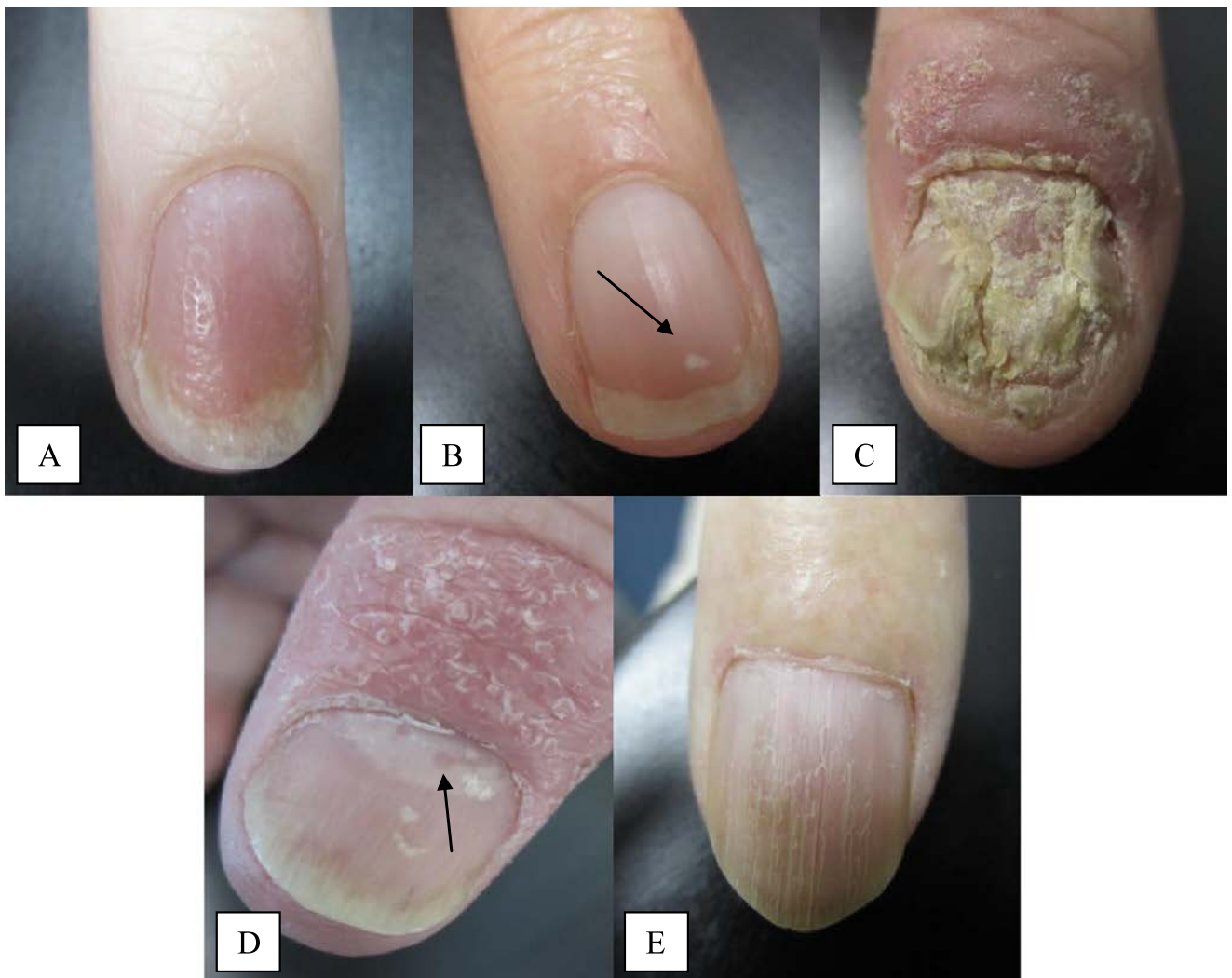

Fig. 1. Nail matrix disease: (A) pitting, (B) leukonychia, (C) crumbling, (D) red spots on the lunula, and (E) onychorrhexis. (For interpretation of the references to color in this figure legend, the reader is referred to the web version of this article.)

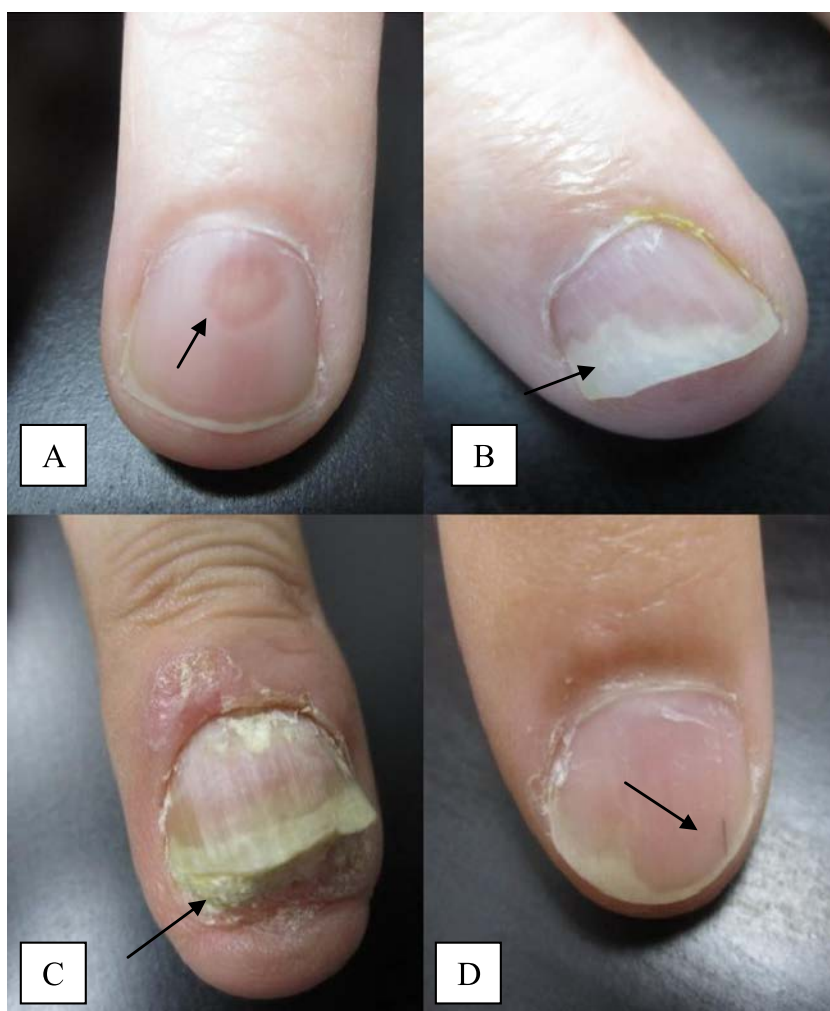

Fig. 2. Nail bed disease: (A) oil spot changes, (B) onycholysis, (C) subungual hyperkeratosis, and (D) splinter hemorrhage.

in the nail plate from inflammation in the middle portion of the nail matrix [29]. With a high degree of inflammation in the nail matrix, nail plate disfiguration or crumbling occurs [28]. Nail ridging (onychorrhexis) can correspond with linear inflammation within the nail matrix [26,29]. Red spots on the lunula are thought to be a consequence of increase blood flow to the nail matrix [30]. Oil spot changes are simply from an increased concentration of dead or damaged cells, as well as proteinaceous fluid [26,28,31]. Inflammation occurring at the tip of the nail causes a detachment of the nail plate and the corresponding lifted appearance of the nail [29]. Subungual hyperkeratosis is caused by increased keratinization on the nail bed, producing a thickening of the nail bed itself [26,29]. As the nail grows out, fragile blood vessels of the nail bed can be irritated, causing blood to extravasate, resulting in red or purple linear discolorations or splinter hemorrhages [28,29].

The subtypes that are noted to be associated with PsA in the literature vary from study to study. In fact, even the overall number of patients with PsA who have nail changes appears to fluctuate greatly from study to study, ranging from those values less than 40% to those greater than 80% [26,32–37]. This review serves to consolidate the literature regarding nail findings in PsA patients.

Material and methods

A review of the literature was completed using PubMed, MEDLINE, and EMBASE in September 2013, encompassing years

1964–2012, in order to determine the current research on the significance of nail changes with PsA. To do this, we searched for the terms “psoriatic arthritis” AND “nail” in titles and abstracts. The articles were reviewed for those that discussed the relationship between nail changes and PsA, and 21 articles were found (Fig. 3). All articles were included regardless of study design or number of participants. Articles that were excluded included those that discussed the relationship between psoriasis and psoriatic nail changes in the absence of PsA. The availability of the full article and those articles printed in English were other criteria used to choose appropriate articles to include in this review.

Results

Among the 21 articles that were used for this review, a large range of variation was found for the percentage of PsA patients who have nail changes: the lowest being 32% and the highest being 97% (Table 2). On average, 66% [standard deviation (SD) 17.7] of PsA patients had nail changes. The Cassell 2007 article was excluded from this calculation as we were unable to calculate such a percentage from their data (Table 3). The oldest two articles reviewed, from 1964 to 1979, had found 83% [38] and 85% [39] of PsA patients to have nail changes, respectively. On the contrary, one of the most recent publications reviewed, a 2012 publication by Love et al. [36], had a large sample size of 183 patients, and the percentage of those with nail findings was found to be 54%.

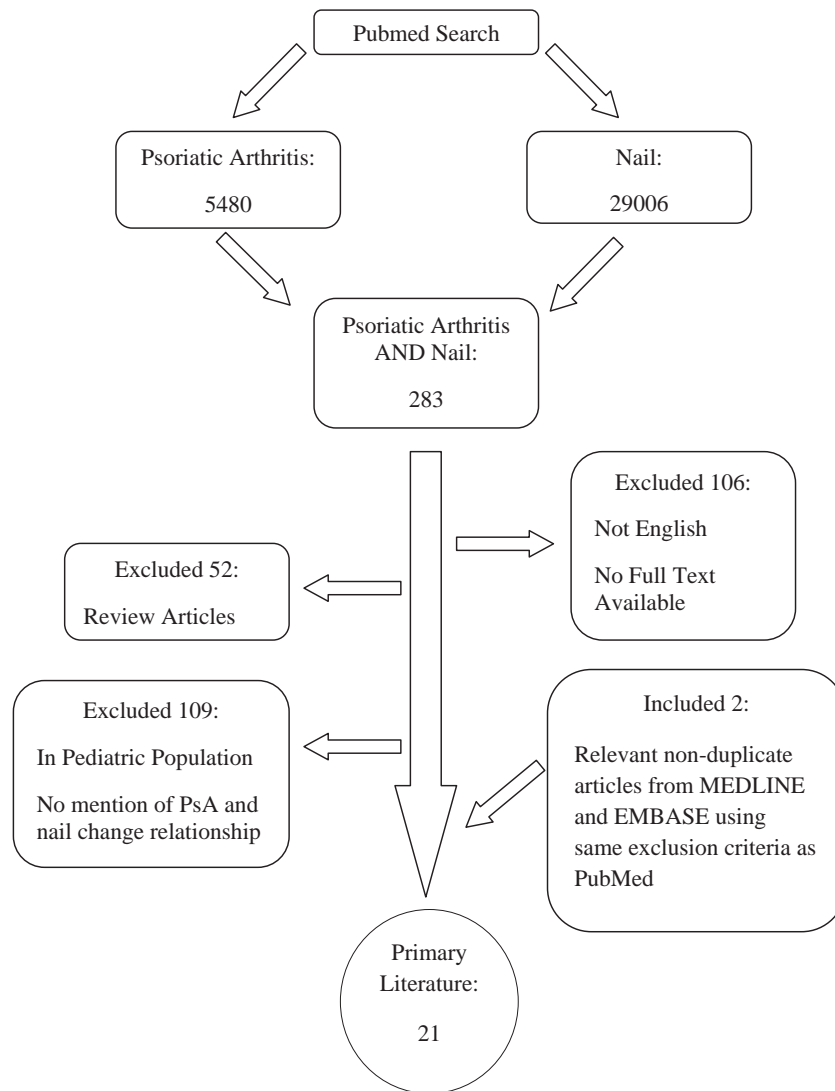


Fig. 3. A flowchart outlining article selection.

Similarly, a study with 233 participants, the greatest number of all the studies reviewed, appeared to have the lowest number of nail changes at only 32% [32]. Two articles had very high rates of nail changes at 97% and 91%, respectively, but low numbers of included patients make it difficult to extrapolate the population overall [29,35]. Interestingly, the 2007 Chandran group separated their findings into those with early PsA (< 2.5 years) and late PsA (> 2.5 years), yet the percentage of each group having nail changes was similar at 77% for early and 74% for late PsA patients [14].

Scoring systems utilized by some of studies reviewed included the Psoriasis Area and Severity Index (PASI), the Psoriasis Nail Severity Score (PNSS), the Nail Psoriasis Severity Index (NAPSI), and the Modified Nail Psoriasis Severity Index (mNAPSI) (Table 3). One study that we included utilized the PASI and no specific nail assessment scoring method [40]. The PASI assesses cutaneous psoriasis and not nail changes by measuring body surface area, erythema, induration, and scale on differently weighted parts of the body [41]. This calculation is often aided by so-called PASI calculators and is thus not typically used clinically [42]. In this study, a positive relationship between the PASI score and swollen joint count was found, but only in those with skin and joint involvement within the same year or with skin changes that appeared before the onset of the arthritis [40]. Williamson et al. [43] highlighted that an association existed in their study

between PNSS of patients and distal interphalangeal (DIP) joint disease, progressive arthritis, as well as the Health Assessment Questionnaire (HAQ) score. Additionally, they found that severe nail involvement, as assessed by PNSS, was associated with severe skin disease [43]. Patients' global arthritis, skin severity, Visual Analog Scale (VAS) for pain, HAQ scores, enthesitis, and dactylitis did not correlate with mNAPSI scores in one study [44]. However, a higher score was associated with higher physician global assessment score, swollen and tender joint count, and patient global nail severity by the same group [44]. Another study using the mNAPSI discovered a relationship between a higher score and clinical DIP joint arthritis but not with radiographic arthritis [45]. Palmou et al. [46] compared mNAPSI scores between psoriasis patients with and without PsA, and no significant difference was found. In 2006, the Scarpa group utilized NAPSI scores and MRI findings to suggest that psoriatic nail changes and distal phalanx involvement typically proceed DIP joint changes [20].

A number of the studies reviewed also differentiated between the subtypes of nail changes that were found to be the most common in PsA patients (Table 4). Two articles by the Love group showed that onycholysis was most strongly related with small joint arthritis, with their earlier 2010 article outlining that the next most common nail changes found after onycholysis were pitting, subungual hyperkeratosis, and, finally, oil spots [36,47]. Other

Table 2
Summary of relevant findings in studies discussing PsA and nail changes

Study	% PsA patients with nail changes (n)	Relationship found between nail changes and PsA
Baker et al. [38]	83% (53)	Increased severity of arthritis related to greater nail involvement, but no relationship was found between arthritis of terminal interphalangeal joints and psoriatic nail changes
Eastmond (1979) [39]	85% (46)	Pitting was the most common nail finding followed by onycholysis, ridging, and subungual hyperkeratosis Non-trauma-induced onycholysis was found only in PsA patients vs. controls Overall, pitting was more frequent in control groups, but total number of pits of > 20 and > 60 was more common in PsA patients
Scarpa (1984) [51]	63% (62)	Nail changes were more common in PsA patients vs. only 37% of those with psoriasis and no PsA Nail changes arose pre-psoriasis in 88% of PsA patients whose joint involvement preceded skin lesions
Torre Alonso (1991) [48]	53% (180)	Onycholysis related to DIP involvement
Jones (1994) [53]	67% (100)	Nail involvement was found in 64% males and 41% females and only in 2% without psoriasis
Elkayam (2000) [40]	63% (70)	Nail disease, but not severity, was more common if DIP joint disease was present PASI score and number of swollen joints with skin and joint onset within same year or skin changes preceding arthritis
Kane (2003) [54]	67% (120)	Nail dystrophy appears to be more common in those with DIP involvement vs. those who do not (80% vs. 58%)
Williamson (2004) [43]	83% (69)	PNSS was associated with DIP joint disease, progressing arthritis, severe skin disease, and HAQ score Median age of onset of psoriasis, nail changes, and arthritis was 28, 32, and 34 years, respectively
Scarpa (2006) [20]	52% (23)	Nail thickening on MRI was in 100% of those with onychopathy vs. 90.9% without any MRI abnormalities of DIP joint in 58% of those with onychopathy vs. 9.1% without MRI results suggest involvement of the nail and the distal phalanx prior to DIP joint involvement Onycholysis, hyperkeratosis, and pitting were the most common nail findings
Cassell (2007) [44]	Unable to calculate percentage 29 PsA patients recruited	The mNAPSI score correlated with physician global assessment score, swollen and tender joint count, and patient global nail severity Patients global arthritis, skin severity VAS scores, HAQ scores, enthesitis, and dactylitis did not correlate with mNAPSI scores
Chandran (2007) [14]	77% (107) early PsA (< 2.5 years) 74% (181) late PsA (> 2.5 years)	With regard to the CASPAR criteria, most patients satisfy the psoriasis, negative RF, and psoriatic nail change criteria
Veerapen (2007) [52]	61% (46)	None discussed and only pitting of > 20 pits/nail was used
Jamshidi (2008) [34]	97% (29)	Psoriatic nail changes were more common in those who have PsA vs. those with psoriasis alone
Soy (2008) [49]	91% (49)	Nail involvement was more common in those with arthritis vs. those without
Love (2010) [47]	79% (154)	Most common nail changes were pitting, onycholysis, leukonychia, and then crumbling and linear pitting Onycholysis strongly associated with small joint involvement Most common nail changes were onycholysis, pitting, subungual hyperkeratosis, and then oil spots
Maejima (2010) [45]	78% (23)	Correlation was established between the mNAPSI score and clinical DIP joint arthritis but not radiographic DIP joint arthritis Most common nail changes in those with DIP joint arthritis were onycholysis and nail plate crumbling, pitting, and then nail bed hyperkeratosis
Yang (2011) [50]	46% (112)	30% of PsA patients had nail and nail fold psoriasis vs. 17% of the control group
Palmou (2011) [46]	51% (121)	Nail changes are more common in those with PsA vs. those with psoriasis alone The mNAPSI score did not differ between psoriasis patients with and without PsA
Gladman (2012) [32]	32% (233)	Splinter hemorrhages and linear pitting was seen more commonly in those with only psoriasis without PsA None discussed
Love (2012) [36]	54% (187)	Onycholysis had a stronger association with arthritis than other types of nail changes
Zisman (2012) [37]	36% (149)	Nail changes positively correlated with DIP joint involvement

studies also noted that onycholysis was the highest nail change subtype found with DIP joint arthritis [45,48]. Compared to the aforementioned Love 2010 study, Maejima et al. [45] established a different order of occurrence of the nail change subtypes with nail plate crumbling being equal to onycholysis, followed by pitting, and then nail bed hyperkeratosis. Two other studies differed from

both with pitting being found more often than onycholysis, and onycholysis being the second most common nail change in PsA patients [38,49]. An older study from 1979 discovered that non-trauma-induced onycholysis appeared to be found only in PsA patients compared to their controls of nonpsoriatic rheumatic patients and nonpsoriatic general medicine patients [39]. Utilizing

Table 3
Outcome measures utilized and associations found

Study	Outcome measure(s)	Associations
Elkayam (2000) [40]	PASI	↑ PASI with ↑ joint count (in those with skin changes preceding arthritis or having the onset of skin and joint changes in the same year)
Williamson (2004) [43]	PNSS	↑ PNSS with ↑ DIP joint disease, HAQ score, and progressive arthritis
Cassell (2007) [44]	mNAPSI	↑ mNAPSI with ↑ PGA, swollen joint count, tender joint count, and patient global nail severity
Maejima (2010) [45]	mNAPSI	↑ mNAPSI with ↑ clinical DIP joint arthritis
Palmou (2011) [46]	mNAPSI	No difference found between patients with PsA and those with psoriasis alone
Scarpa (2006) [20]	NAPSI/MRI	Psoriatic nail changes and DIP involvement typically proceed DIP joint changes

Table 4

Most common nail change observed in PsA patients

Study	Most common nail change	Associations
Love (2012) [36]	Onycholysis	Onycholysis most strongly related with small joint arthritis
Love (2010) [47]	Onycholysis > pitting > subungual hyperkeratosis > oil spots	Onycholysis most strongly related with small joint arthritis
Maejima (2010) [45]	Onycholysis and nail plate crumbling > pitting > nail bed hyperkeratosis	Onycholysis most strongly related with DIP joint arthritis
Torre (1991) [48]	Onycholysis	Onycholysis most strongly related with DIP joint arthritis
Baker (1964) [38]	Pitting > onycholysis > ridging = subungual hyperkeratosis	Greater nail involvement related to increased severity of arthritis
Soy (2008) [49]	Pitting > onycholysis > leukonychia > crumbling = linear pitting	Nail involvement more common in those with arthritis vs. those without
Eastmond (1979) [39]	Cannot conclude	Non-trauma-induced onycholysis found only in PsA patients vs. controls > 20 Pits overall more common in PsA patients vs. controls

these same three groups, this study further described that overall pitting was more common in the two non-PsA groups but that increased number of total pits (> 20 and > 60) then appeared to be more common in the PsA group vs. the non-PsA groups [39].

Three studies from three distinct global populations of patients (Iranian [34], Turkish [49], and Chinese [50]) each showed that psoriatic nail changes as a whole were more common in those with PsA compared to those with psoriasis alone. An older study by Scarpa et al. [51] looked at PsA in psoriasis patients in the Neapolitan area, which also highlighted that nail changes were more common in the presence of PsA instead of psoriasis alone. In Malaysia, 61% of those with PsA were found to have nail changes; however, in this study, nail changes were only classified as greater than 20 pits per nail [52]. The Kane, Jones, and Zisman groups found that onychopathy was more common if DIP joint disease was present, with Jones et al. [53] clarifying that in their study, the severity of nail disease was not associated with DIP joint involvement [37,54].

MRI was used in one study to look more closely at joint and nail changes and it was noticed that nail thickening was found in 100% and DIP joint changes were found in 58% of those with nail disease vs. 90.9% and 9.1% of those without, respectively [20]. Unfortunately, this study was only one of three studies to collect sufficient data to state or speculate any time course relationship between nail, skin, and joint involvement [20,43,51]. The authors suggested that the MRI results hinted that involvement of the nail and distal phalanx may actually proceed DIP joint changes [20]. An older study by Scarpa et al. [51] highlighted that in those whose arthritis preceded the onset of their psoriasis (19.4% of all PsA participants), 88% had nail changes prior to skin changes. The third study, which was by the Williamson group, showed the median age of onset for psoriasis, nail changes, and arthritis was 28, 32, and 34 years, respectively [43].

Gender differences with nail changes were only mentioned in one study. This study found that nail changes were present in 64% of males and 41% females with PsA [48]. Only 2% of participants in this study had nail changes in the absence of psoriasis [48]. Lastly, a group in 2010 found that those with PsA had a higher percentage (30%) of nail fold and nail psoriasis compared to the control group (17%) [45].

Discussion

The theory that the entheses in proximity of the nail bed and the nail matrix are actually anatomically related has been highlighted in a number of studies [20,22,27,55]. Researchers have put forth the idea that the nail changes, and even some of the skin changes associated with PsA, may actually originate from a Koebner response to the underlying joint disease

[20,22,24,27,55]. A study that used MRI imaging in PsA patients demonstrated the close relationship of the nail bed, insertion of the extensor tendon, the DIP joint, and the distal phalanx [23]. It also showed that the inflammation typically begins in the nail and moves proximally to the distal phalanx and later to the DIP joint, which gives credence to the previously mentioned observation that skin disease often appears before joint disease in those with PsA [23]. These high-resolution MRI studies emphasize this relationship further by noting that the nearby extensor tendon fibers and DIP collateral ligaments merge with the nail and actually surround the nail roots, securing everything together [22,55]. The intimate relationship of the nail to enthesal structures appears to apply not only to the nail bed but also the nail matrix [22,55].

The idea behind this DIP joint–nail relationship is supported by a number of studies that we reviewed. In two studies, higher PNSS and mNAPSI scores were discovered to be more common in those with clinically evident DIP joint involvement [43,45]. Onycholysis specifically related to DIP or small joint arthritis in others [47,48]. When severity was reviewed, the Jones group highlighted that although nail disease was more common in those with DIP joint disease, an increase in severity of nail involvement was not associated with worsened DIP arthritis [53]. Three additional studies found similar relationships between higher DIP activity and an increase in onychopathy, with one of these studies using MRI to visualize the DIP joint changes [20,37,54]. A difficult aspect of interpreting this data is the fact that most of the studies did not specifically state that the DIP involvement and nail changes were in fact on the same digit or if this was more of a general relationship. In future studies, we propose a more specific comment toward this, or when possible, analysis of the data digit by digit should be included in order to more accurately relate these findings to each other and transition them into clinical practice.

The use of high-resolution MRI shows enthesitis may be a more common finding than is able to be perceived on clinical exam and may also be associated with nail changes. Given that PsA is already a highly variable disease that can present in multiple ways, monitoring the onset and progression is also a challenge. In this article, we have highlighted some of the relationships that previous studies have found regarding nail changes and PsA, as shown in Table 3. It is difficult to establish a definite recommendation on the significance of nail changes in PsA given the large standard deviation (17.7) of the percentage of PsA patients with nail changes, as well as the overall number of PsA patients looked at in each study, which ranged from 23 to 233. Despite this, we encourage rheumatologists to continue to assess the nails of patients with PsA as it has been shown that when compared to dermatologists, rheumatologists have a high sensitivity at detecting nail disease [43]. Furthermore, from the patient perspective, psoriatic nail changes have been reported in an interview study to cause pain, changes in activities of daily living, and cosmetic issues

in 52%, 58%, and 93%, respectively [56]. An area for further research would be to see if each subtype of nail change individually factors into the effect on the patients' lives.

As displayed in Table 3, only 5 of the 21 studies reviewed utilized a specific nail index tool in their evaluation. The mNAPSI, NAPSI, and PNSS were used in three, one, and one study, respectively [20,43–46]. The tools to evaluate the nails differ among each other. The PNSS assesses pitting, onycholysis, hyperkeratosis, and severe nail deformities with involvement of both sides of the nail [53]. Each finding gives one point, with a corresponding maximum of four per nail [53].

The NAPSI looks at eight of the nine nail changes shown in Figures 1 and 2, excluding onychorrhexis, and divides them into their separate nail bed and nail matrix categories [57]. Each nail is divided into four quadrants and one point is given per quadrant if there is the presence of any nail bed disease in that portion of the nail [57]. The same process is repeated for nail matrix changes, amounting to a maximum of eight points per nail [57]. If a more in-depth analysis is needed, the NAPSI can be altered to give a separate point for each subtype of nail change per quadrant, giving a new total of 32 points per fingernail [57].

Lastly, the mNAPSI also looks at the same eight of nine nail changes in Figures 1 and 2 but combines onycholysis and oil spots together [44]. Pitting, onycholysis/oil spots, and crumbling are graded on a scale from one to three, while the remaining nail changes are only evaluated on being present or absent, totaling a maximum score of 13 per nail [44]. The NAPSI and the mNAPSI are more comprehensive than the PNSS, with the NAPSI being the most comprehensive of the three [57].

Both the NAPSI and the mNAPSI have shown good interobserver reliability, while the mNAPSI is deemed to be shorter and have better feasibility [42,44,58]. Unfortunately, among the studies that used a specific nail index in their evaluation, not all found a relationship between nail changes and PsA. In fact, a 2011 study stated that the mNAPSI score did not differ between psoriasis patients with and without PsA [46]. We were therefore unable to comment on the usefulness of these nail indices in establishing correlations between nail changes and other aspects of PsA given that only a few of the reviewed studies were utilized them. Furthermore, not all the ones who did utilize a nail index found similar results.

It appears that not every article that was reviewed differentiated among the different psoriatic nail change subtypes. Five of the seven studies that did distinguish between the subtypes (Table 4) had onycholysis as the most common [20,36,45,47,48], whereas two other studies both had onycholysis second preceded by pitting [38,49]. Although it seems that onycholysis would therefore be the most common nail change seen in these studies, it would be unwise to confidently state this for a number of reasons. The number of participants in those studies that considered nail change subtypes varied widely, ranging from 23 to 187. Not all studies utilized nail indices to evaluate the nail changes, and those who did, varied with the index chosen. Furthermore, the number of nail change subtypes actually recorded in the different studies varied as well. In order to establish more definite relationships, additional studies should be conducted using a shared nail assessment technique, or if not, consider the same group of subtypes of nail changes for analysis.

The three most common findings in the CASPAR criteria are psoriasis, a negative RF, and psoriatic nail changes, yet a diagnosis of PsA does not necessarily need skin changes as per the CASPAR criteria [14]. It is therefore possible that some studies, such as the article by Baker et al. [38], may have different results because of the recruitment of those with psoriasis into the study followed by a separation of data into those with PsA. This may be important, as other studies have shown different nail changes being more

prevalent in those with psoriasis vs. PsA. One group demonstrated that splinter hemorrhages and linear pitting were seen more commonly in those with psoriasis compared to those with PsA [46], with another showing pitting being the primary finding in psoriasis patients with onycholysis second [59]. Additionally, this type of recruitment may miss a portion of the population with PsA and associated nail changes as some PsA patients may present with arthritis and nail changes even before any clinically evident skin psoriasis [51].

Conclusion

Given the variability of results that were observed in this review, our recommendations are that further large studies on nail changes in patients with PsA should be conducted using the CASPAR criteria as the method of recruitment so as to not restrict participation to those with just skin changes. Evaluating the subtypes of psoriatic nail changes could also be helpful to further show if any one subtype, or even a category of subtypes (nail matrix vs. nail bed changes), is more or less associated with PsA. If such research is completed, a more concrete recommendation could be made based on which subtypes of nail changes rheumatologists should pay special attention to. Additionally, a general agreement upon which nail change scoring system should be used most frequently may also be helpful. Lastly, where facilities exist, continuing the usage of high-resolution MRI to discover additional relationships that may be present between subclinical enthesitis and nail inflammation is encouraged. Our hope is that by highlighting the variability that exists among the current literature with regard to PsA and nail changes, we will encourage further research into this area to shed more light on this complex disease.

Acknowledgment

We thank Dr. Lyn Guenther for her kind assistance in the analysis of nail photographs.

References

- [1] Ibrahim G, Waxman R, Helliwell PS. The prevalence of psoriatic arthritis in people with psoriasis. *Arthritis Rheum* 2009;61:1373–8.
- [2] Love TJ, Gudbjornsson B, Gudjonsson JE, Valdimarsson H. Psoriatic arthritis in Reykjavik, Iceland: prevalence, demographics, and disease course. *J Rheumatol* 2007;34:2082–8.
- [3] Taylor W, Gladman D, Helliwell P, Marchesoni A, Mease P, Mielants H. Classification criteria for psoriatic arthritis: development of new criteria from a large international study. *Arthritis Rheum* 2006;54:2665–73.
- [4] Wilson FC, Icen M, Crowson CS, McEvoy MT, Gabriel SE, Kremers HM. Incidence and clinical predictors of psoriatic arthritis in patients with psoriasis: a population-based study. *Arthritis Rheum* 2009;61:233–9.
- [5] Lloyd P, Ryan C, Menter A. Psoriatic arthritis: an update. *Arthritis* 2012;2012:176298.
- [6] Dougados M, van der Linden S, Juhlin R, Huitfeldt B, Amor B, Calin A, et al. The European Spondylarthropathy Study Group preliminary criteria for the classification of spondylarthropathy. *Arthritis Rheum* 1991;34:1218–27.
- [7] Chandran V, Schentag CT, Brockbank JE, Pellett FJ, Shanmugarajah S, Toloza SM, et al. Familial aggregation of psoriatic arthritis. *Ann Rheum Dis* 2009;68:664–7.
- [8] O'Rielly DD, Rahman P. Genetics of susceptibility and treatment response in psoriatic arthritis. *Nat Rev Rheumatol* 2011;7:718–32.
- [9] Chandran V, Rahman P. Update on the genetics of spondyloarthritis—ankylosing spondylitis and psoriatic arthritis. *Best Pract Res Clin Rheumatol* 2010;24:579–88.
- [10] Ritchlin CT, Haas-Smith SA, Li P, Hicks DG, Schwarz EM. Mechanisms of TNF-alpha- and RANKL-mediated osteoclastogenesis and bone resorption in psoriatic arthritis. *J Clin Invest* 2003;111:821–31.
- [11] Ryan C, Abramson A, Patel M, Menter A. Current investigational drugs in psoriasis. *Expert Opin Investig Drugs* 2012;21:473–87.
- [12] van Kuijk AW, Reinders-Blankert P, Smeets TJ, Dijkmans BA, Tak PP. Detailed analysis of the cell infiltrate and the expression of mediators of synovial inflammation and joint destruction in the synovium of patients with psoriatic arthritis: implications for treatment. *Ann Rheum Dis* 2006;65:1551–7.

- [13] Yago T, Nanke Y, Kawamoto M, Furuya T, Kobashigawa T, Kamatani N, et al. IL-23 induces human osteoclastogenesis via IL-17 in vitro, and anti-IL-23 antibody attenuates collagen-induced arthritis in rats. *Arthritis Res Ther* 2007;9:R96.
- [14] Chandran V, Schentag CT, Gladman DD. Sensitivity of the classification of psoriatic arthritis criteria in early psoriatic arthritis. *Arthritis Rheum* 2007;57:1560–3.
- [15] Dalbeth N, Pui K, Lobo M, Doyle A, Jones PB, Taylor WJ, et al. Nail disease in psoriatic arthritis: distal phalangeal bone edema detected by magnetic resonance imaging predicts development of onycholysis and hyperkeratosis. *J Rheumatol* 2012;39:841–3.
- [16] de Miguel E, Cobo T, Munoz-Fernandez S, Naredo E, Uson J, Acebes JC, et al. Validity of entheses ultrasound assessment in spondyloarthropathy. *Ann Rheum Dis* 2009;68:169–74.
- [17] Filippucci E, Aydin SZ, Karadag O, Salaffi F, Gutierrez M, Direskeneli H, et al. Reliability of high-resolution ultrasonography in the assessment of Achilles tendon enthesopathy in seronegative spondyloarthropathies. *Ann Rheum Dis* 2009;68:1850–5.
- [18] Fournie B, Margari-Coll N, Champetier de Ribes TL, Zabraniecki L, Jouan A, Vincent V, et al. Extrasynovial ultrasound abnormalities in the psoriatic finger. Prospective comparative power-doppler study versus rheumatoid arthritis. *Joint Bone Spine* 2006;73:527–31.
- [19] Scarpa R, Manguso F, Oriente A, Peluso R, Atteno M, Oriente P. Is the involvement of the distal interphalangeal joint in psoriatic patients related to nail psoriasis? *Clin Rheumatol* 2004;23:27–30.
- [20] Scarpa R, Soscia E, Peluso R, Atteno M, Manguso F, Del Puente A, et al. Nail and distal interphalangeal joint in psoriatic arthritis. *J Rheumatol* 2006;33:1315–9.
- [21] Tan AL, Rhodes LA, Marzo-Ortega H, McGonagle D. What imaging has told us about psoriatic arthritis. *Rheumatol Pract* 2007;5:14–6.
- [22] Tan AL, Benjamin M, Toumi H, Grainger AJ, Tanner SF, Emery P, et al. The relationship between the extensor tendon entheses and the nail in distal interphalangeal joint disease in psoriatic arthritis—a high-resolution MRI and histological study. *Rheumatology (Oxford)* 2007;46:253–6.
- [23] Tan AL, Grainger AJ, Tanner SF, Emery P, McGonagle D. A high-resolution magnetic resonance imaging study of distal interphalangeal joint arthropathy in psoriatic arthritis and osteoarthritis: are they the same? *Arthritis Rheum* 2006;54:1328–33.
- [24] McGonagle D, Tan AL, Benjamin M. The biomechanical link between skin and joint disease in psoriasis and psoriatic arthritis: what every dermatologist needs to know. *Ann Rheum Dis* 2008;67:1–4.
- [25] de Berker D. Management of psoriatic nail disease. *Semin Cutan Med Surg* 2009;28:39–43.
- [26] Jiaravuthisan MM, Sasseville D, Vender RB, Murphy F, Muhn CY. Psoriasis of the nail: anatomy, pathology, clinical presentation, and a review of the literature on therapy. *J Am Acad Dermatol* 2007;57:1–27.
- [27] McGonagle D. Enthesitis: an autoinflammatory lesion linking nail and joint involvement in psoriatic disease. *J Eur Acad Dermatol Venereol* 2009;23:9–13.
- [28] Omura EF. Histopathology of the nail. *Dermatol Clin*. 1985;3:531–41.
- [29] Steele G, Emer J, Larian A. The treatment of nail psoriasis: a review. *Psoriasis Forum* 2011;17:188–99.
- [30] Morrissey KA, Rubin AI. Histopathology of the red lunula: new histologic features and clinical correlations of a rare type of erythronychia. *J Cutan Pathol* 2013;40:972–5.
- [31] Salomon J, Szejnietowski JC, Proniewicz A. Psoriatic nails: a prospective clinical study. *J Cutan Med Surg* 2003;7:317–21.
- [32] Gladman DD, Chandran V, Thavaneswaran A, Zummer M. Psoriatic arthritis in Canadian clinical practice: the PsA assessment in rheumatology. *J Rheumatol* 2012;39:1850–3.
- [33] Gladman DD, Helliwell P, Mease PJ, Nash P, Ritchlin C, Taylor W. Assessment of patients with psoriatic arthritis: a review of currently available measures. *Arthritis Rheum* 2004;50:24–35.
- [34] Jamshidi F, Bouzari N, Seirafi H, Farnaghi F, Firooz A. The prevalence of psoriatic arthritis in psoriatic patients in Tehran, Iran. *Arch Iran Med* 2008;11:162–5.
- [35] Lavaroni G, Kokelj F, Pauluzzi P, Trevisan G. The nails in psoriatic arthritis. *Acta Derm Venereol Suppl (Stockh)* 1994;186:113.
- [36] Love TJ, Gudjonsson JE, Valdimarsson H, Gudbjornsson B. Psoriatic arthritis and onycholysis—results from the cross-sectional Reykjavik psoriatic arthritis study. *J Rheumatol* 2012;39:1441–4.
- [37] Zisman D, Eder L, Elias M, Laor A, Bitterman H, Rozenbaum M, et al. Clinical and demographic characteristics of patients with psoriatic arthritis in northern Israel. *Rheumatol Int* 2012;32:595–600.
- [38] Baker H, Golding DN, Thompson M. The nails in psoriatic arthritis. *Br J Dermatol* 1964;76:549–54.
- [39] Eastmond CJ, Wright V. The nail dystrophy of psoriatic arthritis. *Ann Rheum Dis* 1979;38:226–8.
- [40] Elkayam O, Ophir J, Yaron M, Caspi D. Psoriatic arthritis: interrelationships between skin and joint manifestations related to onset, course and distribution. *Clin Rheumatol* 2000;19:301–5.
- [41] Fredriksson T, Pettersson U. Severe psoriasis—oral therapy with a new retinoid. *Dermatologica* 1978;157:238–44.
- [42] Mease PJ. Measures of psoriatic arthritis: tender and swollen joint assessment, Psoriasis Area and Severity Index (PASI), Nail Psoriasis Severity Index (NAPSI), Modified Nail Psoriasis Severity Index (mNAPSI), Mander/Newcastle Enthesitis Index (MEI), Leeds Enthesitis Index (LEI), Spondyloarthritis Research Consortium of Canada (SPARCC), Maastricht Ankylosing Spondylitis Enthesitis Score (MASES), Leeds Dactylitis Index (LDI), Patient Global for Psoriatic Arthritis, Dermatology Life Quality Index (DLQI), Psoriatic Arthritis Quality of Life (PsAQOL), Functional Assessment of Chronic Illness Therapy-Fatigue (FACIT-F), Psoriatic Arthritis Response Criteria (PsARC), Psoriatic Arthritis Joint Activity Index (PsAJAI), Disease Activity in Psoriatic Arthritis (DAPSA), and Composite Psoriatic Disease Activity Index (CPDAI). *Arthritis Care Res* 2011;63:S64–S85.
- [43] Williamson L, Dalbeth N, Dockerty JL, Gee BC, Weatherall R, Wordsworth BP. Extended report: nail disease in psoriatic arthritis—clinically important, potentially treatable and often overlooked. *Rheumatology* 2004;43:790–4.
- [44] Cassell SE, Bieber JD, Rich P, Tutuncu ZN, Lee SJ, Kalunian KC, et al. The modified nail psoriasis severity index: validation of an instrument to assess psoriatic nail involvement in patients with psoriatic arthritis. *J Rheumatol* 2007;34:123–9.
- [45] Maejima H, Taniguchi T, Watarai A, Katsuoka K. Evaluation of nail disease in psoriatic arthritis by using a modified nail psoriasis severity score index. *Int J Dermatol* 2010;49:901–6.
- [46] Palmou N, Marzo-Ortega H, Ash Z, Goodfield M, Coates LC, Helliwell PS, et al. Linear pitting and splinter haemorrhages are more commonly seen in the nails of patients with established psoriasis in comparison to psoriatic arthritis. *Dermatology* 2011;223:370–3.
- [47] Love TJ, Gudjonsson JE, Valdimarsson H, Gudbjornsson B. Small joint involvement in psoriatic arthritis is associated with onycholysis: the Reykjavik psoriatic arthritis study. *Scand J Rheumatol* 2010;39:299–302.
- [48] Torre Alonso JC, Rodriguez Perez A, Arribas Castrillo JM, Ballina Garcia J, Riestra Noriega JL, Lopez Larrea C. Psoriatic arthritis (PA): a clinical, immunological and radiological study of 180 patients. *Br J Rheumatol* 1991;30:245–50.
- [49] Soy M, Karaca N, Umit EU, Bes C, Piskin S. Joint and nail involvement in Turkish patients with psoriatic arthritis. *Rheumatol Int* 2008;29:223–5.
- [50] Yang Q, Qu L, Tian H, Hu Y, Peng J, Yu X, et al. Prevalence and characteristics of psoriatic arthritis in Chinese patients with psoriasis. *J Eur Acad Dermatol Venereol* 2011;25:1409–14.
- [51] Scarpa R, Oriente P, Pucino A, Torella M, Vignone L, Riccio A, et al. Psoriatic arthritis in psoriatic patients. *Br J Rheumatol* 1984;23:246–50.
- [52] Veerapen KK. Pattern of psoriatic arthritis in an Asian population (Malaysia). *APLAR J Rheumatol* 2007;10:287–94.
- [53] Jones SM, Armas JB, Cohen MG, Lovell CR, Evison G, McHugh NJ. Psoriatic arthritis: outcome of disease subsets and relationship of joint disease to nail and skin disease. *Br J Rheumatol* 1994;33:834–9.
- [54] Kane D, Stafford L, Bresnihan B, FitzGerald O. A prospective, clinical and radiological study of early psoriatic arthritis: an early synovitis clinic experience. *Rheumatology (Oxford)* 2003;42:1460–8.
- [55] McGonagle D, Tan AL, Benjamin M. The nail as a musculoskeletal appendage—implications for an improved understanding of the link between psoriasis and arthritis. *Dermatology* 2009;218:97–102.
- [56] de Jong EM, Seegers BA, Gulinck MK, Boezeman JB, van de Kerkhof PC. Psoriasis of the nails associated with disability in a large number of patients: results of a recent interview with 1728 patients. *Dermatology* 1996;193:300–3.
- [57] Rich P, Scher RK. Nail psoriasis severity index: a useful tool for evaluation of nail psoriasis. *J Am Acad Dermatol* 2003;49:206–12.
- [58] Aktan S, Ilknur T, Akin C, Ozkan S. Interobserver reliability of the nail psoriasis severity index. *Clin Exp Dermatol* 2007;32:141–4.
- [59] Tham SN, Lim JJ, Tay SH, Chiew YF, Chua TN, Tan E, et al. Clinical observations on nail changes in psoriasis. *Ann Acad Med Singapore* 1988;17:482–5.