



National  
Comprehensive  
Cancer  
Network®

**NCCN Clinical Practice Guidelines in Oncology™**

# **Anal Carcinoma**

V.1.2010

**Continue**

[www.nccn.org](http://www.nccn.org)

## NCCN Anal Carcinoma Panel Members

\*Paul F. Engstrom, MD/Chair †  
Fox Chase Cancer Center

Peter C. Enzinger, MD †  
Dana-Farber/Brigham and Women's Cancer Center

David P. Ryan, MD ☐  
Massachusetts General Hospital Cancer Center

Juan Pablo Arnoletti, MD ¶  
University of Alabama at Birmingham  
Comprehensive Cancer Center

Marwan G. Fakih, MD †  
Roswell Park Cancer Institute

Leonard Saltz, MD † ‡ ▽  
Memorial Sloan-Kettering Cancer Center

\*Al B. Benson, III, MD †  
Robert H. Lurie Comprehensive Cancer  
Center of Northwestern University

James Fleshman, Jr., MD ¶  
Siteman Cancer Center at Barnes-Jewish Hospital  
and Washington University School of Medicine

David Shibata, MD ¶  
H. Lee Moffitt Cancer Center and Research  
Institute at the University of South Florida

Jordan D. Berlin, MD †  
Vanderbilt-Ingram Cancer Center

Charles Fuchs, MD †  
Dana-Farber/Brigham and Women's Cancer Center

John M. Skibber, MD ¶  
The University of Texas M. D. Anderson Cancer  
Center

J. Michael Berry, MD †  
UCSF Helen Diller Family Comprehensive  
Cancer Center

Jean L. Grem, MD †  
UNMC Eppley Cancer Center at The Nebraska  
Medical Center

William Small, Jr., MD §  
Robert H. Lurie Comprehensive Cancer Center  
of Northwestern University

Yi-Jen Chen, MD, PhD §  
City of Hope Comprehensive Cancer Center

James A. Knol, MD ¶  
University of Michigan Comprehensive Cancer  
Center

Constantinos Sofocleous, MD, PhD ☐  
Memorial Sloan-Kettering Cancer Center

Michael A. Choti, MD ¶  
The Sidney Kimmel Comprehensive Cancer  
Center at Johns Hopkins

Lucille A. Leong, MD †  
City of Hope Comprehensive Cancer Center

James Thomas, MD †  
Arthur G. James Cancer Hospital & Richard J.  
Solove Research Institute at The Ohio State  
University

Harry S. Cooper, MD ≠  
Fox Chase Cancer Center

Edward Lin, MD †  
Fred Hutchinson Cancer Research Center/Seattle  
Cancer Care Alliance

Alan P. Venook, MD † ‡  
UCSF Helen Diller Family Comprehensive  
Cancer Center

Raza A. Dilawari, MD ¶  
St. Jude Children's Research  
Hospital/University of Tennessee Cancer  
Institute

Mary F. Mulcahy, MD ‡  
Robert H. Lurie Comprehensive Cancer Center of  
Northwestern University

\* Christopher Willett, MD §  
Duke Comprehensive Cancer Center

Dayna S. Early, MD ☐  
Siteman Cancer Center at Barnes-Jewish  
Hospital and Washington University School  
of Medicine

Eric Rohren, MD, PhD ☐  
The University of Texas M. D. Anderson Cancer  
Center

**Continue**

† Medical Oncology  
§ Radiotherapy/Radiation oncology  
¶ Surgery/Surgical oncology  
≠ Pathology  
‡ Hematology/Hematology Oncology  
▽ Internal medicine  
☐ Gastroenterology  
☐ Diagnostic/Interventional Radiology  
\* Writing Committee Member

[NCCN Guidelines Panel Disclosures](#)

## Table of Contents

[NCCN Anal Carcinoma Panel Members](#)

[Summary of the Guidelines Updates](#)

[Workup and Treatment - Anal canal cancer \(ANAL-1\)](#)

[Workup and Treatment - Anal margin lesions \(ANAL-2\)](#)

[Follow-up Therapy and Surveillance \(ANAL-3\)](#)

[Principles of Chemotherapy \(ANAL-A\)](#)

[Principles of Radiation Therapy \(ANAL-B\)](#)

[Guidelines Index](#)

[Print the Anal Carcinoma Guideline](#)

**[For help using these documents, please click here](#)**

[Staging](#)

[Discussion](#)

[References](#)

**Clinical Trials:** The NCCN believes that the best management for any cancer patient is in a clinical trial. Participation in clinical trials is especially encouraged.

To find clinical trials online at NCCN member institutions, [click here: nccn.org/clinical\\_trials/physician.html](http://nccn.org/clinical_trials/physician.html)

**NCCN Categories of Evidence and Consensus:** All recommendations are Category 2A unless otherwise specified.

See [NCCN Categories of Evidence and Consensus](#)

These guidelines are a statement of evidence and consensus of the authors regarding their views of currently accepted approaches to treatment. Any clinician seeking to apply or consult these guidelines is expected to use independent medical judgment in the context of individual clinical circumstances to determine any patient's care or treatment. The National Comprehensive Cancer Network makes no representations nor warranties of any kind whatsoever regarding their content, use, or application and disclaims any responsibility for their application or use in any way. These guidelines are copyrighted by National Comprehensive Cancer Network. All rights reserved. These guidelines and the illustrations herein may not be reproduced in any form without the express written permission of NCCN. ©2009.

## Summary of the Guidelines updates

Summary of changes in the 1.2010 version of the Anal Carcinoma Guidelines from the 2.2009 version include:

### [ANAL-1](#)

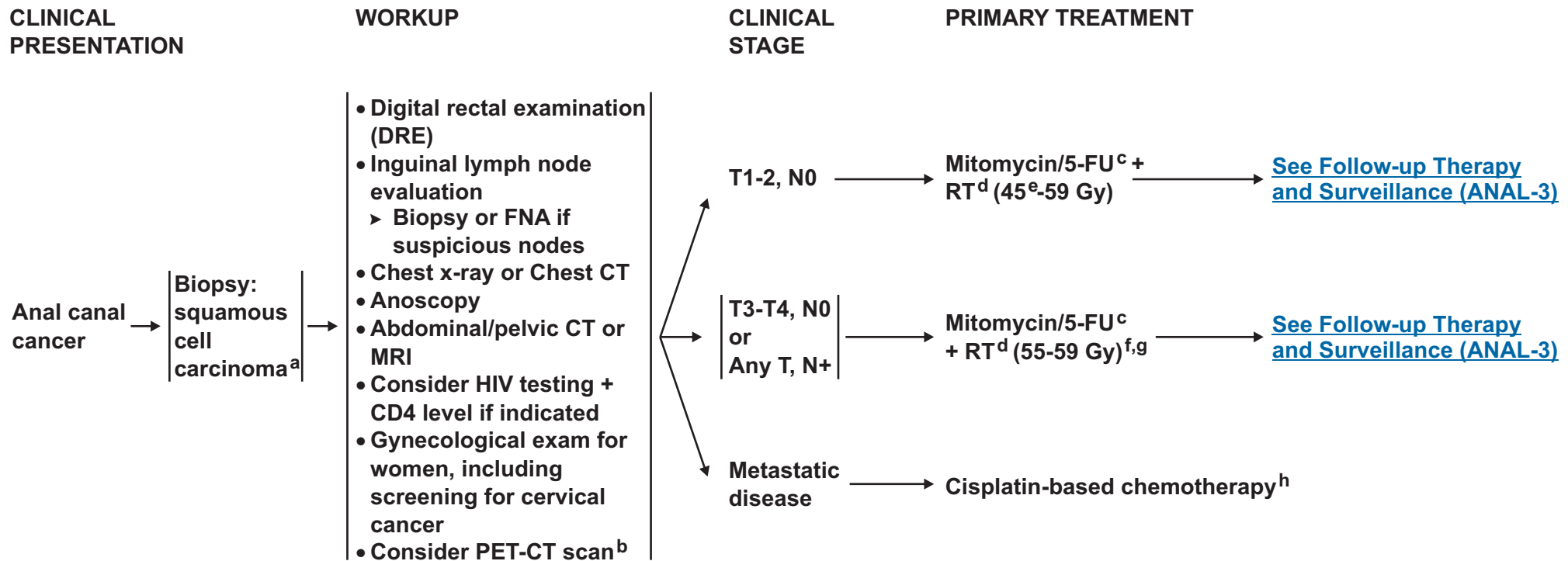
- The recommendation for PET-CT scan was changed to “consider” in the workup section. Footnote “b” is new to the page: “PET-CT scan does not replace a diagnostic CT. The routine use of a PET-CT scan for staging or treatment planning has not been validated.”
- Metastatic disease was added with suggested treatment recommendations.

### [ANAL-2](#)

- Metastatic disease was added with suggested treatment recommendations.

### [ANAL-B](#)

- Principles of Radiation Therapy is a new page.



<sup>a</sup>For melanoma histology, see the [NCCN Melanoma Guidelines](#), for adenocarcinoma, see the [NCCN Rectal Cancer Guidelines](#).

<sup>b</sup>PET-CT scan does not replace a diagnostic CT. The routine use of a PET-CT scan for staging or treatment planning has not been validated.

<sup>c</sup>[See Principles of Chemotherapy ANAL-A.](#)

Ajani JA, Winter KA, Gunderson LL, et al. Fluorouracil, mitomycin, and radiotherapy vs fluorouracil, cisplatin, and radiotherapy for carcinoma of the anal canal: a randomized controlled trial. In a randomized trial, the strategy of using neoadjuvant therapy with 5-FU + cisplatin followed by concurrent therapy with 5-FU + cisplatin + RT was not superior to 5-FU + mitomycin + RT.

<sup>d</sup>[See Principles of Radiation Therapy ANAL-B.](#)

<sup>e</sup>Re-evaluate at 45 Gy, if persistent disease, consider increasing to 55-59 Gy.

<sup>f</sup>Include bilateral inguinal/low pelvic nodal regions based upon estimated risk of inguinal involvement.

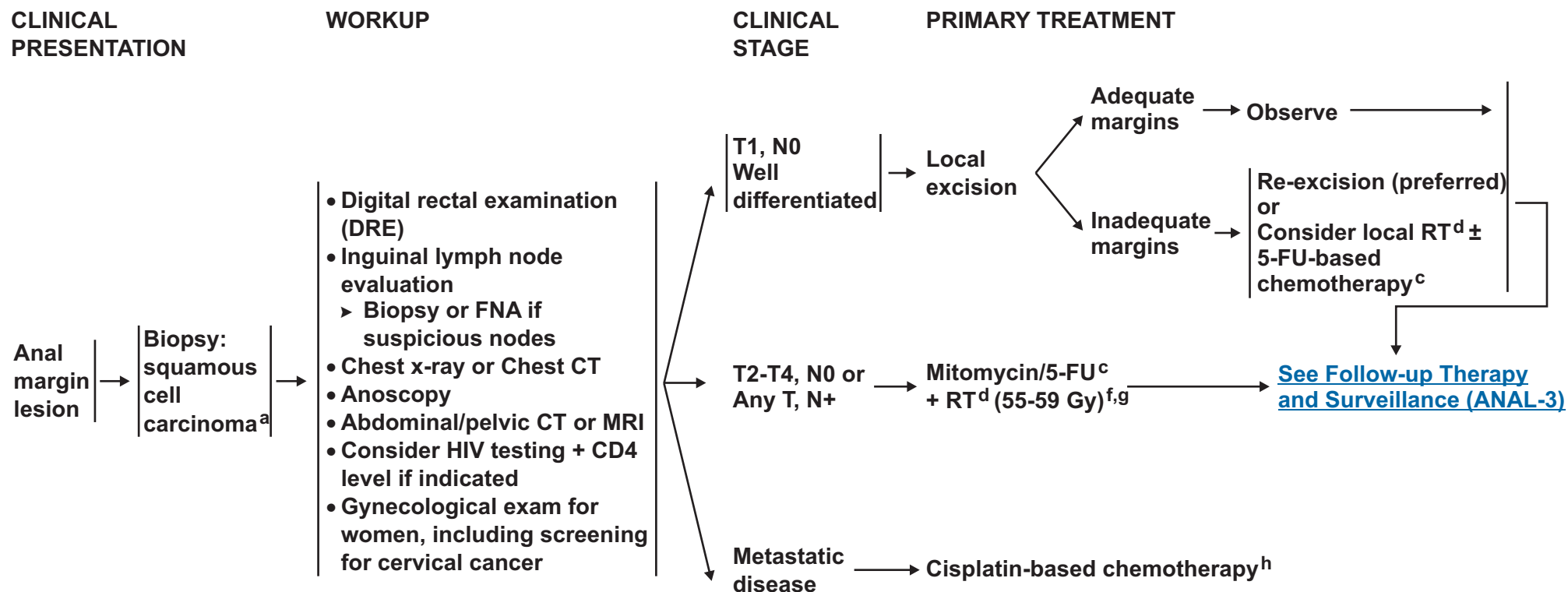
<sup>g</sup>Patients with anal cancer as the first manifestation of HIV/AIDS, may be treated with the same regimen as non-HIV patient. Patients with active HIV/AIDS-related complications or a history of complications (eg, malignancies, opportunistic infections) may not tolerate full-dose therapy or may not tolerate mitomycin and require dosage adjustment or treatment without mitomycin.

<sup>h</sup>Cisplatin/5-fluorouracil recommended for metastatic disease. If this regimen fails, no other regimens have shown to be effective.

[See Principles of Chemotherapy ANAL-A.](#)

**Note:** All recommendations are category 2A unless otherwise indicated.

**Clinical Trials:** NCCN believes that the best management of any cancer patient is in a clinical trial. Participation in clinical trials is especially encouraged.



<sup>a</sup>For melanoma histology, see the [NCCN Melanoma Guidelines](#), for adenocarcinoma, see the [NCCN Rectal Cancer Guidelines](#).

<sup>c</sup>[See Principles of Chemotherapy ANAL-A.](#)

Ajani JA, Winter KA, Gunderson LL, et al. Fluorouracil, mitomycin, and radiotherapy vs fluorouracil, cisplatin, and radiotherapy for carcinoma of the anal canal: a randomized controlled trial. JAMA 2008;299:1914. The strategy of using neoadjuvant therapy with 5-FU + cisplatin followed by concurrent therapy with 5-FU + cisplatin + RT was not superior to 5-FU + mitomycin + RT.

<sup>d</sup>[See Principles of Radiation Therapy ANAL-B.](#)

<sup>e</sup>Re-evaluate at 45 Gy, if persistent disease, consider increasing to 55-59 Gy.

<sup>f</sup>Include bilateral inguinal/low pelvic nodal regions based upon estimated risk of inguinal involvement.

<sup>g</sup>Patients with anal cancer as the first manifestation of HIV/AIDS, may be treated with the same regimen as non-HIV patient. Patients with active HIV/AIDS-related complications or a history of complications (eg, malignancies, opportunistic infections) may not tolerate full-dose therapy or may not tolerate mitomycin and require dosage adjustment or treatment without mitomycin.

<sup>h</sup>Cisplatin/5-fluorouracil recommended for metastatic disease. If this regimen fails, no other regimens have shown to be effective.

[See Principles of Chemotherapy ANAL-A.](#)

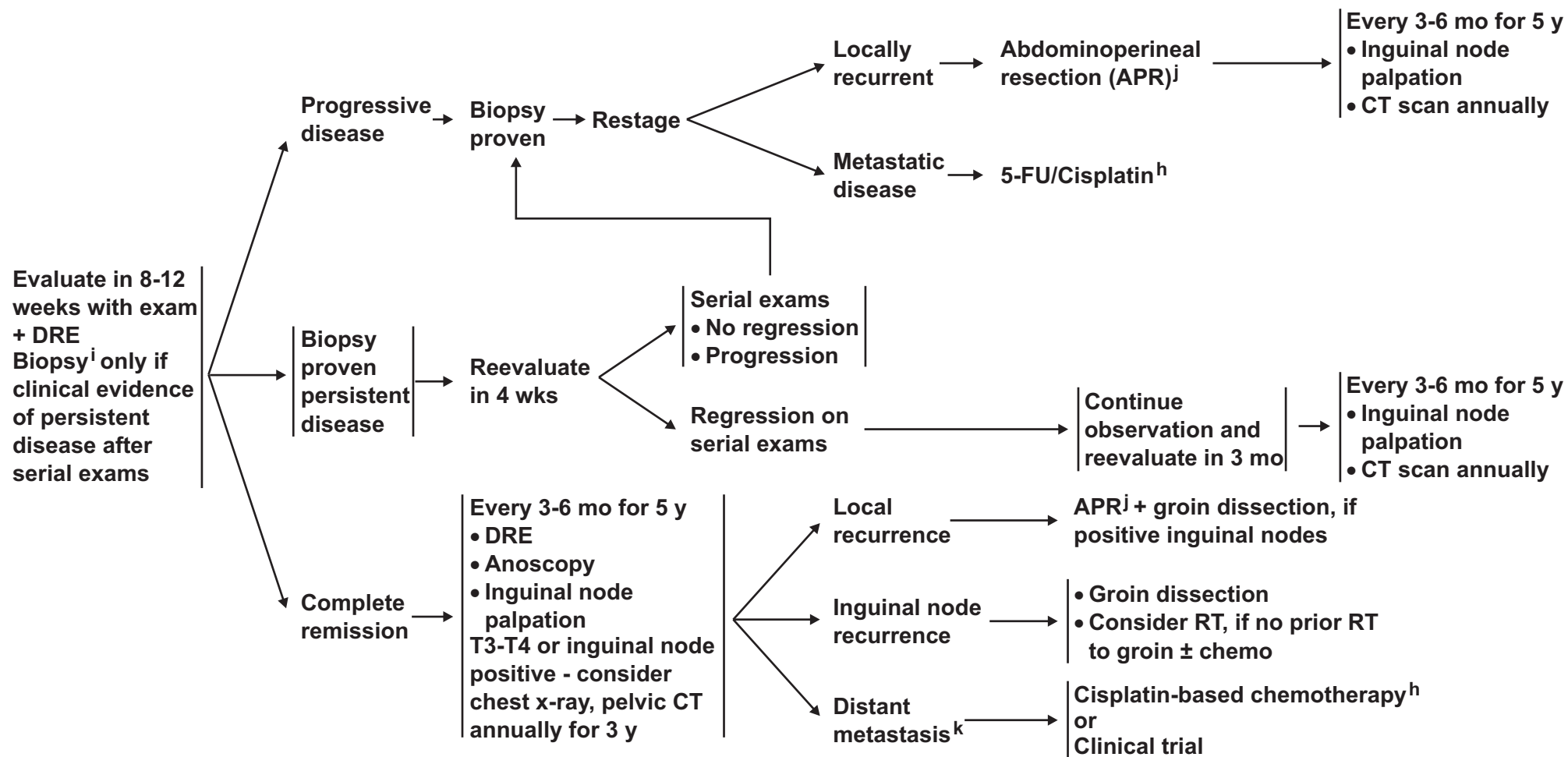
**Note:** All recommendations are category 2A unless otherwise indicated.

**Clinical Trials:** NCCN believes that the best management of any cancer patient is in a clinical trial. Participation in clinical trials is especially encouraged.

FOLLOW-UP

SURVEILLANCE

LOCALLY RECURRENT/METASTATIC DISEASE



<sup>h</sup>Cisplatin/5-fluorouracil recommended for metastatic disease. If this regimen fails, no other regimens have shown to be effective.

[See Principles of Chemotherapy ANAL-A.](#)

<sup>i</sup>If patient with an initially tethered tumor returns 6 weeks postop RT with a mobile but suspicious mass, consider biopsy.

<sup>j</sup>Consider muscle flap reconstruction.

<sup>k</sup>There is no evidence supporting resection of metastatic disease.

**Note:** All recommendations are category 2A unless otherwise indicated.

**Clinical Trials:** NCCN believes that the best management of any cancer patient is in a clinical trial. Participation in clinical trials is especially encouraged.

## PRINCIPLES OF CHEMOTHERAPY

**Localized cancer****5-FU + Mitomycin + RT<sup>1,2</sup>****5-FU 1000 mg/m<sup>2</sup>/d IV days 1-4 and 29-32****Mitomycin 10 mg/m<sup>2</sup> IV bolus days 1 and 29****Concurrent radiotherapy 1.8 Gy/d for 5 weeks to 45 Gy****Metastatic Cancer****5-FU + Cisplatin<sup>3</sup>****5-FU 1000 mg/m<sup>2</sup>/d IV days 1-5****Cisplatin 100 mg/m<sup>2</sup> IV day 2****Repeat every 4 weeks**

<sup>1</sup>Ajani JA, Winter KA, Gunderson LL, et al. Fluorouracil, mitomycin, and radiotherapy vs fluorouracil, cisplatin, and radiotherapy for carcinoma of the anal canal: a randomized controlled trial. JAMA 2008;299:1914-1921.

<sup>2</sup>Flam M, John M, Pajak TF, et al. Role of mitomycin in combination with fluorouracil and radiotherapy, and of salvage chemoradiation in the definitive nonsurgical treatment of epidermoid carcinoma of the anal canal: results of a phase III randomized intergroup study. J Clin Oncol 1996;14:2527

<sup>3</sup>Faivre C, Rougier P, Ducreux M, et al. 5-fluorouracil and cisplatin combination chemotherapy for metastatic squamous-cell anal cancer. Bull Cancer 1999;86:861-5.

**Note:** All recommendations are category 2A unless otherwise indicated.

**Clinical Trials:** NCCN believes that the best management of any cancer patient is in a clinical trial. Participation in clinical trials is especially encouraged.



PRINCIPLES OF RADIATION THERAPY<sup>1</sup>

- All patients should receive a minimum dose of 45 Gy in 25 fractions of 1.8 Gy over 5 weeks to the primary cancer with supervoltage radiation (photon energy of > 6 mV) using anteroposterior-posteroanterior (AP-PA) or multifield techniques.
- Initial radiation fields include the pelvis, anus, perineum, and inguinal nodes, with the superior field border at L5-S1 and the inferior border to include the anus with a minimum margin of 2.5 cm. around the anus and tumor. The lateral border of AP fields includes the lateral inguinal nodes as determined from bony landmarks or imaging (computed tomography), but lateral inguinal nodes are not routinely included in the PA fields to allow adequate sparing of the femoral heads.
- After a dose of 30.6 Gy in 17 fractions, the superior field extent is reduced to the bottom of the sacroiliac joints and an additional 14.4 Gy is given in 8 fractions (total dose of 45 Gy in 25 fractions/5weeks), with additional field reduction off node-negative inguinal nodes after 36 Gy.
- For patients treated with an AP-PA rather than 4-field technique, an anterior electron boost (matched to the PA exit field) is used to bring the lateral inguinal region to the minimum dose of 30.6 Gy.
- For patients with T3, T4, node-positive disease or patients with T2 residual disease after 45 Gy, the intent is usually to deliver an additional boost of 9 to 14 Gy in 1.8 to 2 Gy fractions (total dose of 54-59 Gy in 30-32 fractions over 6.0-7.5 weeks).
- The target volume for boost field 2 is the original primary tumor volume/node plus a 2- to 2.5 cm. margin. Treatment field options include a multifield photon approach (AP-PA plus paired laterals, PA + laterals, or other) or a direct perineal boost with electrons or photons with the patient in lithotomy position.
- Intensity modulated radiation therapy in addition to three dimensional conformal radiation therapy may be used in the treatment of patients with anal cancer.

<sup>1</sup>Ajani JA, Winter KA, Gunderson LL, et al. Fluorouracil, mitomycin, and radiotherapy vs fluorouracil, cisplatin, and radiotherapy for carcinoma of the anal canal. JAMA 2008;299:1914-1921.

**Note:** All recommendations are category 2A unless otherwise indicated.

**Clinical Trials:** NCCN believes that the best management of any cancer patient is in a clinical trial. Participation in clinical trials is especially encouraged.

## Staging Anal Canal Cancer

**Table 1****2002 American Joint Committee on Cancer (AJCC)  
Staging System for Anal Canal Cancer\*†****Primary Tumor (T)**

- TX** Primary tumor cannot be assessed  
**T0** No evidence of primary tumor  
**Tis** Carcinoma in situ  
**T1** Tumor 2 cm or less in greatest dimension  
**T2** Tumor more than 2 cm but not more than 5 cm in greatest dimension  
**T3** Tumor more than 5 cm in greatest dimension  
**T4** Tumor of any size invades adjacent organ(s), e.g., vagina, urethra, bladder†

**Regional Lymph Nodes (N)**

- NX** Regional lymph nodes cannot be assessed  
**N0** No regional lymph node metastasis  
**N1** Metastasis in perirectal lymph node(s)  
**N2** Metastasis in unilateral internal iliac and/or inguinal lymph node(s)  
**N3** Metastasis in perirectal and inguinal lymph nodes and/or bilateral internal iliac and/or inguinal lymph nodes

**Distant Metastasis (M)**

- MX** Distant metastasis cannot be assessed  
**M0** No distant metastasis  
**M1** Distant metastasis

[Staging for Anal Margin Cancer, see ST-2](#)

**Stage Grouping**

Stage 0	Tis	N0	M0
Stage I	T1	N0	M0
Stage II	T2	N0	M0
	T3	N0	M0
Stage IIIA	T1	N1	M0
	T2	N1	M0
	T3	N1	M0
	T4	N0	M0
Stage IIIB	T4	N1	M0
	Any T	N2	M0
	Any T	N3	M0
Stage IV	Any T	Any N	M1

**Histologic Grade (G)**

- GX** Grade cannot be assessed  
**G1** Well differentiated  
**G2** Moderately differentiated  
**G3** Poorly differentiated  
**G4** Undifferentiated

\*Used with the permission of the American Joint Committee on Cancer (AJCC), Chicago, Illinois. The original and primary source for this information is the *AJCC Cancer Staging Manual, Sixth edition* (2002) published by Springer-Verlag New York. (For more information, visit [www.cancerstaging.net](http://www.cancerstaging.net).) Any citation or quotation of this material must be credited to the AJCC as its primary source. The inclusion of this information herein does not authorize any reuse or further distribution without the expressed written permission of Springer-Verlag New York on behalf of the AJCC.

†Direct invasion of the rectal wall, perirectal skin, subcutaneous tissue, or the sphincter muscle(s) is not classified as T4.

## Staging Anal Margin Cancer

**Table 2**

**2002 American Joint Committee on Cancer (AJCC)  
TNM Staging System for Skin Cancer\***

**Primary Tumor (T)**

- TX** Primary tumor cannot be assessed  
**T0** No evidence of primary tumor  
**Tis** Carcinoma *in situ*  
**T1** Tumor 2 cm or less in greatest dimension  
**T2** Tumor more than 2 cm but not more than 5 cm in greatest dimension  
**T3** Tumor more than 5 cm in greatest dimension  
**T4** Tumor invades deep extradermal structures (i.e., cartilage, skeletal muscle, or bone)

*Note:* In the case of multiple simultaneous tumors, the tumor with the highest T category will be classified and the number of separate tumors will be indicated in parentheses, e.g., T2 (5).

**Regional Lymph Nodes (N)**

- NX** Regional lymph nodes cannot be assessed  
**N0** No regional lymph node metastasis  
**N1** Regional lymph node metastasis

**Distant Metastasis (M)**

- MX** Distant metastasis cannot be assessed  
**M0** No distant metastasis  
**M1** Distant metastasis

**Stage Grouping**

<b>Stage 0</b>	Tis	N0	M0
<b>Stage I</b>	T1	N0	M0
<b>Stage II</b>	T2	N0	M0
	T3	N0	M0
<b>Stage III</b>	T4	N0	M0
	Any T	N1	M0
<b>Stage IV</b>	Any T	Any N	M1

**Histologic Grade (G)**

- GX** Grade cannot be assessed  
**G1** Well differentiated  
**G2** Moderately differentiated  
**G3** Poorly differentiated  
**G4** Undifferentiated

\*Used with the permission of the American Joint Committee on Cancer (AJCC), Chicago, Illinois. The original and primary source for this information is the *AJCC Cancer Staging Manual, Sixth edition* (2002) published by Springer-Verlag New York. (For more information, visit [www.cancerstaging.net](http://www.cancerstaging.net).) Any citation or quotation of this material must be credited to the AJCC as its primary source. The inclusion of this information herein does not authorize any reuse or further distribution without the expressed written permission of Springer-Verlag New York on behalf of the AJCC.

†Anal margin tumors are biologically comparable to other skin tumors and therefore are classified by this schema.

## Discussion

### NCCN Categories of Evidence and Consensus

**Category 1:** The recommendation is based on high-level evidence (e.g. randomized controlled trials) and there is uniform NCCN consensus.

**Category 2A:** The recommendation is based on lower-level evidence and there is uniform NCCN consensus.

**Category 2B:** The recommendation is based on lower-level evidence and there is nonuniform NCCN consensus (but no major disagreement).

**Category 3:** The recommendation is based on any level of evidence but reflects major disagreement.

**All recommendations are category 2A unless otherwise noted.**

### Overview

An estimated 5,290 new cases (2,100 men and 3,190 women) of anal cancer (involving the anus, anal canal, or the anorectum) will occur in the United States in 2009, accounting for approximately 1.9% of digestive system cancers.<sup>1</sup> It has been estimated that 710 deaths due to anal cancer will occur in the U.S. in 2009. Although considered to be a rare type of cancer, the incidence rate of invasive anal carcinoma in the U.S. increased by approximately 1.6-fold for men and 1.5-fold for women from the period of 1973-1979 to 1994-2000<sup>2</sup> (see section entitled Risk Factors, below).

This manuscript summarizes the NCCN clinical practice guidelines for managing squamous cell anal carcinoma which represents the most common histologic form of the disease. Other types of cancers occurring in the anal region, such as adenocarcinoma or melanoma, are addressed in other NCCN guidelines (ie, anal adenocarcinoma and anal melanoma are managed according to the [NCCN Rectal Cancer](#)

[Guidelines](#) and the [NCCN Melanoma Guidelines](#), respectively). The recommendations in these guidelines are classified as category 2A except where noted, meaning that there is uniform NCCN consensus, based on lower-level evidence that the recommendation is appropriate. The panel unanimously endorses patient participation in a clinical trial over standard or accepted therapy.

### Risk Factors

Anal carcinoma has been associated with human papilloma virus (HPV) infection (anal-genital warts); a history of receptive anal intercourse or sexually transmitted disease; a history of cervical, vulvar, or vaginal cancer; immunosuppression after solid organ transplantation or human immunodeficiency virus (HIV) infection; and smoking.<sup>3-5</sup> Currently, it is believed that the association between anal carcinoma and persistent infection with a high-risk form of HPV (eg, HPV-16; HPV-18) is strongest.<sup>4,6,7</sup> For example, a study of tumor specimens from 60 pathology laboratories showed that HPV-16 was detected in 84% and 0% of the anal and rectal cancer specimens, respectively.<sup>4</sup> In addition, results of a systematic review of peer-reviewed studies of anal cancer including detection of HPV DNA published up until July 2007 showed the prevalence of HPV-16/18 to be 72% in patients with invasive anal cancer.<sup>7</sup> Furthermore, suppression of the immune system by the use of immunosuppressive drugs or HIV infection is likely to facilitate persistence of HPV infection of the anal region.<sup>8,9</sup> In the HIV-infected population, the standardized incidence rate of anal carcinoma per 100,000 person-years in the U.S., estimated to be 19.0 in 1992-1995, increased to 78.2 during 2000-2003.<sup>10</sup> This result is likely to reflect both the survival benefits of highly active antiretroviral therapy (HAART) and the lack of an impact of HAART on the progression of anal cancer precursors.

## Anatomy/Histology

The anal region is comprised of the anal canal and the anal margin, dividing anal cancers into 2 categories. The anal canal is the more proximal portion of the anal region. Various definitions of the anal canal exist (eg, functional/surgical anal canal; anatomic anal canal; and histological anal canal) which are based on particular physical/anatomic landmarks or histological characteristics of the anal canal. The functional anal canal is defined by the sphincter muscles. The superior border of the functional anal canal, separating it from the rectum, has been defined as the palpable upper border of the anal sphincter and puborectalis muscles of the anorectal ring. It is approximately 3 to 4 cm in length and its inferior border starts at the anal verge, the lowermost edge of the sphincter muscles which corresponds to the introitus of the anal orifice.<sup>3,11,12</sup> This definition is primarily used in the radical surgical treatment of anal cancer. In describing anal cancers, more useful definitions include histologic characteristics of the mucosal lining of the anal region.<sup>13,14</sup> The mucosa of the anal canal is predominantly formed by squamous epithelium, in contrast to the mucosa of the rectum which is lined with glandular epithelium.<sup>3,11</sup> The most superior aspect of anal canal is a 1 to 2 cm zone between the anal and rectal epithelium which has rectal, urothelial, and squamous histologic characteristics.<sup>3,11</sup> The most inferior aspect of the anal canal, approximately at the anal verge, corresponds to the area where the mucosa lined with modified squamous epithelium transitions to an epidermis-lined anal margin. The anal margin starts at the anal verge, and includes the perianal skin over a 5 cm radius around the anal verge.<sup>11</sup> The terms anal margin and perianal skin are frequently used synonymously.<sup>11,15</sup>

## Pathology

Most primary cancers of the anal canal are of squamous cell histology.<sup>11,13</sup> The second edition of the World Health Organization (WHO) classification system of anal carcinoma designated all squamous cell carcinoma variants of the anal canal as cloacogenic and

identified subtypes as large cell keratinizing, large cell non-keratinizing (transitional), or basaloid.<sup>16</sup> It has been reported that squamous cell cancers in the more proximal region of the anal canal are more likely to be non-keratinizing and less differentiated.<sup>3</sup> However, the terms cloacogenic, transitional, keratinizing and basaloid have been removed from the current WHO classification system of anal canal carcinoma, and all subtypes have been included under a single generic heading of squamous cell carcinoma.<sup>14-18</sup> Reasons for this change include the following: both cloacogenic (which is sometimes used interchangeably with the term basaloid) and transitional tumors are now considered to be non-keratinizing tumors; it has been reported that both keratinizing and nonkeratinizing tumors have a similar natural history and prognosis<sup>15</sup>; and a mixture of cell types frequently characterize histologic specimens of squamous cell carcinomas of the anal canal.<sup>11,15-18</sup> No distinction between squamous anal canal tumors on the basis of cell type has been made in the guidelines. Other less common anal canal tumors include adenocarcinomas of the anal glands, small cell and undifferentiated cancers, and melanomas.<sup>11</sup> Squamous cell carcinomas of the anal margin are more likely than anal canal tumors to be well-differentiated and keratinizing,<sup>3</sup> but they are not characterized in the guidelines according to cell type. The presence of skin appendages (eg, sweat glands) in anal margin tumors can distinguish them from anal canal tumors.<sup>15</sup> However, it is not always possible to distinguish between anal canal and anal margin squamous cell carcinoma since tumors can involve both areas.<sup>15</sup>

Lymph drainage of anal cancer tumors is dependent on the location of the tumor in the anal region: cancers in the perianal skin and the region of the anal canal distal to the dentate line drain mainly to the superficial inguinal nodes; lymph drainage at and proximal to the dentate line is directed toward the perirectal nodes and to some of the nodes of the internal iliac system; more proximal cancers drain to nodes of the inferior mesenteric system.<sup>11</sup> Therefore, distal anal cancers present

with a higher incidence of inguinal node metastasis, although the lymphatic drainage systems throughout the anal canal are not isolated from each other.<sup>11</sup>

## Staging

The TNM staging system for anal canal cancer developed by the American Joint Committee on Cancer (AJCC) is detailed in [Table 1](#)<sup>14</sup> Since current recommendations for the primary treatment of anal canal cancer do not involve a surgical excision, most tumors are staged clinically with an emphasis on the size of the primary tumor as determined by direct examination and microscopic confirmation.<sup>14</sup> An incisional tumor biopsy is required. Rectal ultrasound to determine depth of tumor invasion is not used in the staging of anal cancer (see Clinical Presentation/Evaluation, below). The AJCC TNM system used for anal margin cancer ([Table 2](#)) is the same system used to stage skin cancer since the 2 types of cancers have a similar biology.<sup>14</sup>

Lymph node staging is based on location of involved nodes in the staging of anal canal cancer: N1 designates metastasis in one or more perirectal nodes; N2 represents metastasis in unilateral internal iliac nodes and/or inguinal node(s); and N3 designates metastasis in perirectal and inguinal nodes and/or bilateral internal iliac and/or inguinal nodes. For anal margin cancer, N0 and N1 simply represent the absence or presence of regional nodal metastasis. However, because initial therapy of anal cancer does not typically involve surgery, the true lymph node status may not be determined accurately. Biopsy of inguinal nodes is recommended if tumor metastasis to these nodes is suspected.

The prognosis of anal carcinoma is related to the size of the primary tumor and the presence of lymph node metastases.<sup>14</sup> Approximately 60% to 70% of anal carcinoma tumors are initially staged as I or II.<sup>19, 20</sup> The 5-year survival rate for patients with tumors that are that are

treated with chemoRT and  $\leq 2$  cm or  $> 5$  cm have been reported to be approximately 80%, and less than 50%, respectively.<sup>11</sup> The following 5-year overall survival rates according to the disease stage were determined in a very recent analysis of 19,199 patients with anal canal cancer included in the National Cancer Data Base from 1985-2000: stage I, 69.5%; stage II, 59.0%; stage III, 40.6%; and stage IV, 18.7%.<sup>21</sup> Reports of the extent of nodal involvement associated with anal cancers at presentation have varied widely, with most values ranging between 10% and 40%.<sup>11, 15, 19-23</sup> Although there have been reports that the extent of nodal involvement is correlated with the T-stage of the tumor,<sup>23</sup> other studies have not supported this conclusion.<sup>20</sup> In a surgical series of patients with anal cancer who underwent an abdominoperineal resection (APR), it was noted that pelvic nodal metastases were often under 0.5 cm,<sup>24</sup> suggesting that routine radiological evaluation with CT and PET scan may not be reliable in the determination of lymph nodal involvement. In a retrospective study of 270 patients treated for anal canal cancer with RT between 1980 and 1996, synchronous inguinal node metastasis was observed in 6.4% of patients with tumors staged as T1 or T2, and increased to 16% in patients with T3 or T4 tumors.<sup>19</sup> In patients with N2-3 disease, survival was related to T-stage rather than nodal involvement with respective 5-year survival rates of 72.7% and 39.9% for patients with T1-T2 and T3-T4 tumors; however, the number of patients involved in this analysis was small.

## Management of Anal Carcinoma

### Clinical Presentation/Evaluation

Most patients with anal carcinoma present with rectal bleeding. Approximately 30% of patients with anal carcinoma have either pain or the sensation of a rectal mass.<sup>3</sup> The recommendations of the NCCN Anal Carcinoma Guidelines panel for the clinical evaluation of patients with suspected anal canal or anal margin cancer are the same, with the exception of consideration of positron emission tomography (PET)/CT

scan which is not included in the workup of anal margin cancers (see [ANAL-1](#); [ANAL-2](#)). Following confirmation of squamous cell carcinoma by biopsy, the panel recommends a thorough examination/evaluation, including a careful DRE, palpation of the inguinal lymph nodes, and an anoscopic examination with biopsy of suspicious lesions. Assessment of T stage is primarily performed through clinical examination. Assessment of inguinal lymph node involvement for either anal margin or anal canal cancer is performed by fine-needle aspiration (FNA) biopsy and/or excisional biopsy of nodes found to be enlarged by either clinical or radiological examination. Evaluation of pelvic lymph nodes with computed tomography (CT) or magnetic resonance imaging (MRI) of the pelvis is also recommended. These methods can also provide information on whether tumor involves other abdominal/pelvic organs. Since veins of the anal region are part of the venous network associated with systemic circulation,<sup>11</sup> chest x-ray or chest CT scan is performed to evaluate for pulmonary metastasis. PET/CT scanning has been reported to be useful in the evaluation of pelvic nodes, even in patients with anal canal cancer who have normal-sized lymph nodes on CT imaging,<sup>25-27</sup> although the panel does not consider PET/CT to be a replacement for a diagnostic CT. Furthermore, the panel noted that the routine use of a PET/CT scan for staging or treatment planning has not been validated. HIV testing and measurement of CD4 level is suggested as the risk of anal carcinoma has been reported in some studies to be higher in HIV-positive patients.<sup>28</sup> Gynecological exam, including cervical cancer screening, is suggested for female patients due to the association of anal cancer and HPV.<sup>4</sup>

### Primary Treatment of Anal Carcinoma

In the past, patients with invasive anal carcinoma were routinely treated with an APR; however, local recurrence rates were high, 5-year survival was only 40% to 70%, and the morbidity with a permanent colostomy was considerable.<sup>3</sup> Currently, concurrent chemoradiation (chemoRT) alone, as an alternative to an APR, is the recommended primary

treatment for patients with anal canal cancer, or anal margin cancer characterized as T2-T4,N0 or node positive. Well differentiated anal margin lesions characterized as T1,N0 can be treated with margin-negative local excision alone.

In 1974, Nigro and coworkers observed complete tumor regression in some patients with anal carcinoma treated with preoperative 5-fluorouracil- (5-FU-) based concurrent chemoRT including either mitomycin or porfiromycin, suggesting that it might be possible to cure anal carcinoma without surgery and permanent colostomy.<sup>29</sup> Subsequent nonrandomized studies using similar regimens and varied doses of chemotherapy and radiation provided support for this conclusion.<sup>30,31</sup> Results of randomized trials evaluating the efficacy and safety of administering chemotherapy with RT support the use of combined modality therapy in the treatment of anal cancer.<sup>32</sup> Results from a phase III study from the European Organization for Research and Treatment of Cancer (EORTC) comparing use of chemoRT (5-FU plus mitomycin) and RT alone in the treatment of anal carcinoma showed that patients in the chemoRT arm had a higher rate of locoregional control and a longer colostomy-free interval.<sup>33</sup> The United Kingdom Coordinating Committee on Cancer Research (UKCCCR) randomized trial confirmed that chemoRT with 5-FU and mitomycin was more effective in controlling local disease than RT alone (relative risk=0.54, 95% CI, 0.42-0.69; P<0.0001), although no significant differences in overall survival were observed.<sup>34</sup>

A number of studies have addressed the efficacy and safety of specific chemoRT regimens (involving chemotherapy regimens containing both 1 and 2 agents) used in the treatment of anal carcinoma. In a phase III Intergroup study,<sup>35</sup> patients receiving chemoRT with the combination of 5-FU and mitomycin had a lower colostomy rate (9% versus 22%; P = 0.002) and a higher disease-free survival (73% vs 51%; P = 0.0003) compared with patients receiving chemoRT with 5-FU alone, indicating

that mitomycin is an important component of chemoRT in the treatment of anal carcinoma. Survival rate at 4 years was the same for the two groups reflecting the ability to salvage recurrent patients with an APR. Cisplatin as a substitute for mitomycin was evaluated in several phase II trials and results suggested that cisplatin-containing and mitomycin-containing chemoRT were comparable.<sup>36</sup> Use of 5-FU-based chemoRT combined with either mitomycin or cisplatin in the treatment of patients with anal carcinoma has been investigated in the randomized Intergroup Radiation Therapy Oncology Group (RTOG) 98-11 trial.<sup>37</sup> In this study, 644 patients were randomly assigned to receive either neoadjuvant 5-FU plus cisplatin for 2 cycles followed by concurrent chemoRT with 5-FU and cisplatin, or concurrent chemoRT with 5-FU and mitomycin. No significant differences were observed in the primary endpoint, disease-free survival (DFS) (54% vs. 60%; P=0.17), or in 5-year overall survival (70% vs. 75%; P=0.10). However, the colostomy rate was significantly higher in the group receiving cisplatin compared to the mitomycin-containing arm (19% vs. 10%; P=0.02).

Since the 2 treatment arms in the RTOG 98-11 trial differed with respect to use of either cisplatin or mitomycin in concurrent chemoRT as well as inclusion of neoadjuvant chemotherapy in the cisplatin-containing arm of the trial, it is not presently possible to attribute the increased rate of colostomy to the substitution of cisplatin for mitomycin or to the use of induction chemotherapy.<sup>38,39</sup> A secondary combined multivariate analysis of the 2 arms of this trial showed pretreatment tumor size >5 cm was predictive of an increased likelihood of colostomy.<sup>40</sup> A summary of some of the ongoing clinical trials involving patients with anal cancer has been presented.<sup>39</sup>

Results from the phase III UK ACT II trial, the largest trial ever conducted in patients with anal cancer, have recently been presented.<sup>41</sup> In this study over 900 patients with newly diagnosed anal cancer were randomly assigned to primary treatment with either 5-FU/mitomycin or

5-FU/cisplatin in concomitant chemoRT. A continuous course (ie, no treatment gap) of radiation of 50.4 Gy was administered in both arms, and patients in each arm were further randomized to receive 2 cycles of maintenance therapy with 5-FU and cisplatin or no maintenance therapy. At a median follow-up of 3 years, no differences were observed in the primary endpoint of complete response rate in either arm for the chemoRT comparison or in the primary endpoint of recurrence-free survival for the comparison of maintenance therapy versus no maintenance therapy. In addition, a secondary endpoint colostomy did not show differences based on the chemotherapeutic components of chemoRT. These results demonstrate that replacement of mitomycin with cisplatin in chemoRT does not increase the rate of complete response nor does administration of maintenance therapy decrease the rate of disease recurrence following primary treatment with chemoRT in patients with anal cancer.

The optimal dose and schedule of RT for anal carcinoma also continues to be explored, in addition to the schedule of chemotherapy relative to RT. Most studies have delivered 5-FU as a protracted 96 to 120 hour infusion during the first and fifth weeks of RT, and bolus injection of mitomycin is typically given on the first or second day of the 5-FU infusion.<sup>11</sup> The effects of RT dose and RT schedule have been evaluated in a number of nonrandomized studies. In one study of patients with early-stage (T1 or Tis) anal canal cancer, most patients were effectively treated with RT doses of 40-50 Gy for Tis lesions and 50-60 Gy for T1 lesions.<sup>42</sup> In another study in which the majority of patients had stage II/III anal canal cancer, local control of disease was higher in the group of patients receiving RT doses  $\geq$ 50 Gy.<sup>43</sup> In a third study, patients with T3, T4 or lymph node-positive tumors, RT doses of  $\geq$  54 Gy administered within 60 days were associated with increased local control.<sup>44</sup>



There is evidence that treatment interruptions (ie, gaps), either planned or required by treatment-related toxicity, can compromise the effectiveness of treatment.<sup>27</sup> In the phase II RTOG 92-08 trial, planned 2 week treatment breaks in the delivery of chemoRT to patients with anal cancer were associated with increased local regional failure rates and lower colostomy-free survival rates when compared with results from previous trials in which lower RT doses were used without a mandated treatment break, although the study was not powered for comparison, the number of patients involved was small, and the differences were not significant.<sup>45</sup> In addition, the absence of a planned treatment break in the ACT-II trial was considered to be at least partially responsible for the high relapse-free survival rates (75% at 3 years) observed in that study.<sup>41</sup> Although results of other studies have also supported the benefit of delivery of chemoRT over shorter time periods,<sup>46,47</sup> treatment breaks in the delivery of chemoRT are frequently required (eg, up to 50% of patients in clinical trials undergo treatment breaks) since chemoRT-related toxicities are common. For example, it has been reported that one-third of patients receiving primary chemoRT for anal carcinoma at RT doses of 30 Gy in 3 weeks develop acute anoproctitis and dermatitis, increasing to one-half to two-thirds of patients when RT doses of 54-60 Gy are administered in 6 to 7 weeks.<sup>11</sup> Some of the reported late side effects of chemoRT include urgency and increased frequency of defecation, chronic perineal dermatitis, dyspareunia, and impotence. In some cases, severe late RT complications, such as anal ulcers, stenosis, and necrosis, may necessitate surgery involving colostomy.<sup>48</sup> In addition, results from a retrospective cohort study of data from the Surveillance, Epidemiology, and End Results (SEER) registry showed the risk of subsequent pelvic fracture to be 3-fold higher in older women undergoing radiation therapy for anal cancer compared with older women with anal cancer who did not receive radiation therapy.<sup>49</sup>

There is an increasing body of literature suggesting that toxicity can be reduced with advanced radiation delivery techniques.<sup>27,50-53</sup> Intensity modulated radiation therapy (IMRT) utilizes detailed beam shaping to target specific volumes and limit the exposure of normal tissue.<sup>50,53</sup> Multiple pilot studies have demonstrated reduced toxicity while maintaining local control using IMRT. For example, the rates of grade 3/4 dermatologic toxicity in a cross-study comparison of a multicenter study of 53 patients with anal cancer treated with concurrent 5-FU/mitomycin C chemotherapy and IMRT with those observed in the 5-FU/mitomycin C arm of the randomized RTOG 98-11 study involving use of conventional 3-D radiation therapy were 38%/0% and 43%/5%, respectively.<sup>37,51</sup> No decrease in treatment effectiveness or local control rates was observed with use of IMRT, although the small sample size and short duration of follow-up limit the conclusions drawn from such a comparison. IMRT studies (eg, RTOG 0529) are now ongoing to further evaluate its benefit in the treatment of anal cancer. Its use requires expertise and careful application to avoid reduction in local control probability. The clinical target volumes for anal cancer used in the RTOG -0529 trial have been described in detail.<sup>54</sup> ([http://atc.wustl.edu/protocols/rtog-closed/0529/ANAL\\_Ca\\_CTVs\\_5-21-07\\_Final.pdf](http://atc.wustl.edu/protocols/rtog-closed/0529/ANAL_Ca_CTVs_5-21-07_Final.pdf)).

As discussed above (see [Risk Factors](#)), patients with HIV/AIDS have been reported to be at increased risk of anal carcinoma.<sup>28,32</sup> Although most studies evaluating outcomes of patients with HIV/AIDS treated with chemoRT for anal carcinoma are retrospective,<sup>32</sup> there is evidence to indicate that patients with anal carcinoma as the first manifestation of HIV/AIDS (especially those with a CD4 count of  $\geq 200/\text{mm}^3$ ) may be treated with the same regimen as non-HIV patients.<sup>55,56</sup> Furthermore, in a recent retrospective cohort study of 1184 veterans (15% of whom tested positive for HIV) diagnosed with squamous cell carcinoma of the anus between 1998 and 2004 no differences with respect to receipt of treatment or 2-year survival rates were observed when the group of

patients infected with HIV was compared with the group of patients testing negative for HIV.<sup>57</sup> This conclusion was supported by a study of 36 consecutive patients with anal cancer including 19 immunocompetent and 17 immunodeficient (14 HIV-positive) patients which showed no differences in the efficacy or toxicity of chemoRT.<sup>58</sup> Nevertheless, a recent cohort comparison of 40 HIV-positive patients with 81 HIV-negative patients with anal canal cancer found local relapse rates to be 4 times higher in the HIV-positive group (62% vs. 13%) at 3 years and significantly higher rates of severe acute skin toxicity for patients infected with HIV.<sup>59</sup> However, no differences in rates of complete response or 5-year overall survival were observed between the 2 groups in that study. Other factors to consider include compliance with HAART (although it is unclear whether increased compliance with HAART is associated with better outcomes following chemoRT for anal carcinoma<sup>55,60</sup>) and performance status.<sup>32</sup> Patients with active HIV/AIDS-related complications or a history of complications (eg, malignancies, opportunistic infections) may not tolerate full-dose therapy and may require dosage adjustment.

#### **Recommendations for the Primary Treatment of Anal Canal Cancer**

Anal canal cancer is treated with chemoRT (5-FU/mitomycin plus RT) as the primary treatment option (see [ANAL-1](#); [ANAL-A](#)).

Recommendations regarding RT doses follow those used in the RTOG 98-11 trial (see [ANAL-B](#)).<sup>40</sup> All patients should receive a minimum RT dose of 45 Gy to the primary cancer. The recommended initial RT dose is 30.6 Gy to the pelvis, anus, perineum, and inguinal nodes (see [ANAL-B](#)). Field reduction off the superior field border and node-negative inguinal nodes is recommended after delivery of 30.6 Gy and 36 Gy, respectively. Patients with disease clinically staged as T3-T4, N0, T any with nodal involvement, or T2 residual disease after 45 Gy should receive an additional boost of 10-14 Gy. The consensus of the panel is that IMRT may be used in place of 3-D conformal RT in the treatment of anal carcinoma. Two cycles of 5-FU/mitomycin to be

delivered during the first and fifth week of RT are recommended (see [ANAL-A](#)). Cisplatin-based chemotherapy is recommended to treat metastatic disease (see [Recommendations for the Treatment of Locally Recurrent/Metastatic Disease \(Anal Canal/Margin Cancer\)](#)).<sup>61</sup>

#### **Recommendations for the Primary Treatment of Anal Margin Cancer**

Anal margin lesions can be treated with either local excision or chemoRT depending on the clinical stage. Primary treatment for patients with T1N0 well differentiated anal margin cancers is by local excision with adequate margins (see [ANAL-2](#)). If the margins are not adequate, re-excision is the preferred treatment option. Local RT with or without 5-FU-based chemotherapy can be considered as an alternative treatment option when surgical margins are inadequate. T2 to T4 and node-positive anal margin cancers are treated with mitomycin/5-FU plus RT (with doses and scheduling as described for anal canal cancers). Inclusion of bilateral inguinal/low pelvic nodal regions in the RT field should be considered for more advanced cancers (see [ANAL-2](#); [ANAL-A](#); [ANAL-B](#)). Cisplatin-based chemotherapy is recommended to treat metastatic disease (see [Recommendations for the Treatment of Locally Recurrent/Metastatic Disease \(Anal Canal/Margin Cancer\)](#)).<sup>61</sup>

#### **Follow-up and Surveillance Following Primary Treatment**

Following primary treatment, the surveillance and follow-up treatment recommendations for anal margin and anal canal cancer are the same. Patients are re-evaluated by DRE between 8 and 12 weeks after completion of primary treatment with chemoRT (see [ANAL-3](#)). A biopsy is performed only if presence of disease is suspected after serial DRE. Disease can continue to regress for a period of many months following completion of chemoRT, and the likelihood of a false-positive result is high.<sup>62,63</sup> Some of the indications for biopsy include new hard-edged ulcer, enlarging mass, or increasing pain. Following re-evaluation, patients are classified according to whether they have a complete

remission of disease, progressive disease, or persistent disease. In one study, persistent disease was defined as presence of biopsy-proven carcinoma within 6 months of completion of chemoRT.<sup>64</sup> Although a clinical assessment of progressive disease requires histologic confirmation, patients can be classified as having a complete remission without biopsy verification, if clinical evidence of disease is absent. Patients with biopsy results of persistent disease but without evidence of progression may be managed with close follow-up (in 4 weeks) to see if further regression occurs. If no regression of disease is observed on serial examination or if progression of disease occurs, further intensive treatment is indicated (see [Recommendations for the Treatment of Progressive Disease](#), below). Patients who continue to show evidence of disease regression should be re-evaluated clinically in 3 months (see [ANAL-3](#)). The panel recommends that patients classified as having a complete remission of disease should undergo more intensive surveillance every 3-6 months for 5 years, including DRE, anoscopic evaluation and inguinal node palpation. A chest x-ray and a pelvic CT scan should be considered annually for 3 years for patients with locally advanced disease (ie, T3/T4 tumor) or node-positive cancers.

### **Treatment of Progressive/Recurrent/Metastatic Anal Carcinoma**

Despite the effectiveness of chemoRT in the primary treatment of anal carcinoma, rates of locoregional failure of up to 40% have been reported,<sup>65</sup> and radical salvage surgery with an APR has been the treatment of choice for these patients.<sup>64</sup> Some of the disease characteristics that have been associated with higher recurrence rates following chemoRT include higher T stage and higher N stage.<sup>66</sup> In several surgical series involving a minimum of 25 patients undergoing a salvage APR for anal carcinoma, 5-year survival rates of 39%-64% were observed, although complication rates were reported to be high in some of these studies.<sup>18, 64, 67-70</sup> Factors associated with worse prognosis following salvage APR include an initial presentation of node-

positive disease and RT doses < 55 Gy used in the treatment of primary disease.<sup>64</sup> It has been shown that for patients undergoing an APR which had been preceded by RT, closure of the perineal wound using rectum abdominus myocutaneous flap reconstruction resulted in decreased perineal wound complications.<sup>71</sup>

It has been reported that the most common sites of metastasis outside of the pelvis include the liver, lung, and extrapelvic lymph nodes.<sup>72</sup> Since anal carcinoma is a rare cancer and only 10%-20% of patients with anal carcinoma present with metastatic disease,<sup>72</sup> only limited data are available on this population of patients, although there is some evidence to indicate that chemotherapy with a fluoropyrimidine-based regimen plus cisplatin has some benefit in patients with metastatic anal carcinoma.<sup>61,72-75</sup>

### ***Recommendations for the Treatment of Progressive Disease (Anal Canal/Margin Cancer)***

Evidence of progression found on DRE should be followed by biopsy as well as restaging with CT and/or PET imaging. Patients with biopsy-proven progressive disease are candidates for an APR. Muscle flap reconstruction of the perineum should be considered because of the extensive previous RT to the area (see [ANAL-3](#)). These patients should be re-evaluated every 3-6 months for 5 years, including clinical evaluation of nodal metastasis (ie, inguinal node palpation) and CT scan annually.

### ***Recommendations for the Treatment of Locally Recurrent/Metastatic Disease (Anal Canal/Margin Cancer)***

Patients who are in complete remission should be evaluated every 3-6 months for 5 years as described (see [ANAL-3](#); [Follow-up and Surveillance Following Primary Treatment](#)). Treatment recommendations for patients who develop a local recurrence include an APR; muscle flap reconstruction of the perineum should be considered. Inguinal node dissection is reserved for recurrence in that

area, and can be performed without an APR in cases where recurrence is limited to the inguinal nodes. Patients who develop inguinal node metastasis who do not undergo an APR can be considered for RT to the groin with or without chemotherapy if limited prior RT to the groin was given. Treatment recommendations for patients who develop a distant metastasis should be individualized, and local treatment, as described above, could be considered for the locally-symptomatic patient. There is no evidence supporting resection of metastatic disease. Treatment recommendations for patients with metastatic anal carcinoma include platinum-based chemotherapy (see [ANAL-A](#)) or enrollment in a clinical trial. Currently, no other regimens have been shown to be effective in these patients following failure of 5-FU/cisplatin.

### Summary

The NCCN Anal Carcinoma Guidelines panel believes that a multidisciplinary approach, including physicians from gastroenterology, medical oncology, surgical oncology, radiation oncology, and radiology is necessary for treating patients with anal carcinoma.

Recommendations for the primary treatment of anal margin cancer and anal canal cancer are very similar and include 5-FU/mitomycin-based RT, although small, well differentiated anal margin lesions can be treated with margin-negative local excision alone. Follow-up clinical evaluations are recommended for all patients with anal carcinoma since salvage is possible. Patients with biopsy-proven evidence of locoregional progressive disease following primary treatment should undergo an APR. Following complete remission of disease, patients with a local recurrence should be treated with an APR with a groin dissection if there is clinical evidence of inguinal nodal metastasis, and patients with a regional recurrence in the inguinal nodes can be treated with an inguinal node dissection, with consideration of RT with or without chemotherapy, if limited prior RT to the groin was given. Patients with evidence of extrapelvic metastatic disease should be

treated with cisplatin-based chemotherapy or enrolled in a clinical trial. The panel endorses the concept that treating patients in a clinical trial has priority over standard or accepted therapy.

## References

1. Jemal A, Siegel R, Ward E, et al. Cancer statistics, 2009. *CA Cancer J Clin.* 2009;59:225-229.
2. Johnson LG, Madeleine MM, Newcomer LM, et al. Anal cancer incidence and survival: the surveillance, epidemiology, and end results experience, 1973-2000. *Cancer.* 2004;101:281-288.
3. Ryan DP, Compton CC, Mayer RJ. Carcinoma of the anal canal. *N Engl J Med.* 2000;342:792-800.
4. Frisch M, Glimelius B, van den Brule AJ, et al. Sexually transmitted infection as a cause of anal cancer. *N Engl J Med.* 1997;337:1350-1358.
5. Daling JR, Madeleine MM, Godefroy Johnson L, et al. Human papillomavirus, smoking, and sexual practices in the etiology of anal cancer. *Cancer.* 2004;101:270-280.
6. De Vurst H, Clifford GM, Nascimento MC, et al. Prevalence and type distribution of human papillomavirus in carcinoma and intraepithelial neoplasia of the vulva, vagina and anus: a meta-analysis. *Int J Cancer.* 2009;124:1626-1636.
7. Hoots BE, Palefsky JM, Pimenta JM, Smith JS. Human papillomavirus type distribution in anal cancer and anal intraepithelial lesions. *Int J Cancer.* 2009;124:2375-2383.
8. Gervaz P, Allal AS, Villiger P, et al. Squamous cell carcinoma of the anus: another sexually transmitted disease. *Swiss Med Wkly.* 2003;133:353-359.
9. Dezube BJ. HIV-associated anal squamous cell cancer: an otherwise preventable disease. *J Clin Oncol.* 2006;24:4516-4517.
10. Patel P, Hanson DL, Sullivan PS, et al. Incidence of types of cancer among HIV-infected persons compared with the general population in the United States, 1992-2003. *Ann Intern Med.* 2008;148:728-736.
11. Cummings BJ, Ajani JA, Swallow CJ. Cancer of the anal region. In: DeVita VT, Lawrence TS, Rosenberg, SA, ed. *Cancer: Principles and practice of oncology*, 8th ed. Philadelphia, Pa.: Lippincott, Williams & Wilkins; 2008.
12. Nivatvongs S, Stern HS, Fryd DS. The length of the anal canal. *Dis Colon Rectum.* 1981;24:600-601.
13. Rickert RR, Compton CC. Protocol for the examination of specimens from patients with carcinomas of the anus and anal canal: a basis for checklists. Cancer Committee of the College of American Pathologists. *Arch Pathol Lab Med.* 2000;124:21-25.
14. Greene F, Page D, Fleming I, Fritz A. *AJCC Cancer Staging Manual.* New York: Springer-Verlag; 2002.
15. Fenger C, Fritsch M, Marti MC, Parc R. Tumours of the anal canal. In *World Health Organisation Classification of Tumours. Pathology and genetics of tumours of the digestive system*, Hamilton SR, Aaltonen LA (eds.). IARC Press: Lyon 2000;145-155.
16. Jass JR, Sobin LH. *Histological typing of intestinal tumours.* Heidelberg: Springer-Verlag; 1989.
17. Fenger C. Prognostic factors in anal carcinoma. *Pathology.* 2002;34:53-57.
18. Cummings BJ. Current management of anal canal cancer. *Semin Oncol.* 2005; 32(suppl 9): S123-S128.
19. Gerard JP, Chapet O, Samiei F, et al. Management of inguinal lymph node metastases in patients with carcinoma of the anal canal: experience in a series of 270 patients treated in Lyon and review of the literature. *Cancer.* 2001;92:77-84.
20. Boman BM, Moertel CG, O'Connell MJ, et al. Carcinoma of the anal canal. A clinical and pathologic study of 188 cases. *Cancer.* 1984;54:114-125.
21. Bilimoria KY, BEntrem DJ, Rock CE, et al. Outcomes and prognostic factors for squamous-cell carcinoma of the anal cancer:

analysis of patients from the National Cancer Data Base. *Dis Colon Rectum*. 2009;52:624-631.

22. Fuchshuber PR, Rodriguez-Bigas M, Weber T, Petrelli NJ. Anal canal and perianal epidermoid cancers. *J Am Coll Surg*. 1997;185:494-505.

23. Frost DB, Richards PC, Montague ED, et al. Epidermoid cancer of the anorectum. *Cancer*. 1984;53:1285.

24. Wade DS, Herrera L, Castillo NB, Petrelli NJ. Metastases to the lymph nodes in epidermoid carcinoma of the anal canal studied by a clearing technique. *Surg Gynecol Obstet*. 1989;169:238-242.

25. Cotter SE, Grigsby PW, Siegel BA, et al. FDG-PET/CT in the evaluation of anal carcinoma. *Int J Radiat Oncol Biol Phys*. 2006;65:720-725.

26. Trautmann TG, Zuger JH. Positron Emission Tomography for pretreatment staging and posttreatment evaluation in cancer of the anal canal. *Mol Imaging Biol*. 2005;7:309-313.

27. Pepek JM, Willet CG, Czito BG, et al. Radiation therapy advances for treatment of anal cancer. *J Natl Compr Canc Netw*. 2010;7: (in press).

28. Frisch M, Goodman MT. Human papillomavirus-associated carcinomas in Hawaii and the mainland U.S. *Cancer*. 2000;88:1464-1469.

29. Nigro ND, Vaitkevicius VK, Considine B, Jr. Combined therapy for cancer of the anal canal: a preliminary report. *Dis Colon Rectum*. 1974;17:354-356.

30. Cummings BJ, Keane TJ, O'Sullivan B, Wong CS, Catton CN. Epidermoid anal cancer: treatment by radiation alone or by radiation and 5-fluorouracil with and without mitomycin C. *Int J Radiat Oncol Biol Phys*. 1991;21:1115-1125.

31. Papillon J, Chassard JL. Respective roles of radiotherapy and surgery in the management of epidermoid carcinoma of the anal margin. Series of 57 patients. *Dis Colon Rectum*. 1992;35:422-429.

32. Uronis HE, Bendell JC. Anal cancer: an overview. *Oncologist*. 2007;12:524-534.

33. Bartelink H, Roelofsen F, Eschwege F, et al. Concomitant radiotherapy and chemotherapy is superior to radiotherapy alone in the treatment of locally advanced anal cancer: results of a phase III randomized trial of the European Organization for Research and Treatment of Cancer Radiotherapy and Gastrointestinal Cooperative Groups. *J Clin Oncol*. 1997;15:2040-2049.

34. Epidermoid anal cancer: results from the UKCCCR randomised trial of radiotherapy alone versus radiotherapy, 5-fluorouracil, and mitomycin. UKCCCR Anal Cancer Trial Working Party. UK Coordinating Committee on Cancer Research. *Lancet*. 1996;348:1049-1054.

35. Flam M, John M, Pajak TF, et al. Role of mitomycin in combination with fluorouracil and radiotherapy, and of salvage chemoradiation in the definitive nonsurgical treatment of epidermoid carcinoma of the anal canal: results of a phase III randomized intergroup study. *J Clin Oncol*. 1996;14:2527-2539.

36. Crehange G, Bosset M, Lorchel F, et al. Combining cisplatin and mitomycin with radiotherapy in anal carcinoma. *Dis Colon Rectum*. 2006;50:43-49.

37. Ajani JA, Winter KA, Gunderson LL, et al. Fluorouracil, mitomycin, and radiotherapy vs. fluorouracil, cisplatin, and radiotherapy for carcinoma of the anal canal. A randomized controlled trial. *JAMA*. 2008;299:1914-1921.

38. Eng C, Crane CH, Rodriguez-Bigas MA. Should cisplatin be avoided in the treatment of locally advanced squamous cell carcinoma of the anal canal? *Nature Clinical Practice Gastroenterology & Hepatology*. 2009;6:16-17.

39. Czito BG, Willett CG. Current management of anal canal cancer. *Gastrointestinal Cancers.Curr Oncol Rep.* 2009;11:186-192.
40. Ajani JA, Winter KA, Gunderson LL, et al. US Intergroup Anal Carcinoma Trial: Tumor diameter predicts for colostomy. *J Clin Oncol.* 2009;27:1116-1121.
41. James R, Wan S, Glynne-Jones D, et al. A randomised trial of chemoradiation using mitomycin or cisplatin with or without maintenance cisplatin/5-FU in squamous cell carcinoma of the anus. ACT II. *J Clin Oncol.* 2009;27:LBA4009.
42. Ortholan C, Ramaioli A, Peiffert D, et al. Anal canal carcinoma: early-stage tumors < or =10 mm (T1 or Tis): therapeutic options and original pattern of local failure after radiotherapy. *Int J Radiat Oncol Biol Phys.* 2005;62:479-485.
43. Ferrigno R, Nakamura RA, Dos Santos Novaes PE, et al. Radiochemotherapy in the conservative treatment of anal canal carcinoma: retrospective analysis of results and radiation dose effectiveness. *Int J Radiat Oncol Biol Phys.* 2005;61:1136-1142.
44. Huang K, Haas-Kogan D, Weinberg V, Krieg R. Higher radiation dose with a shorter treatment duration improves outcome for locally advanced carcinoma of anal canal. *World J Gastroenterol.* 2007;13:895-900.
45. Konski A, Garcia M Jr, John M, et al. Evaluation of planned treatment breaks during radiation therapy for anal cancer: update of RTOG 92-08. *Int J Radiat Oncol Biol Phys.* 2008;72:114-118.
46. Graf R, Wust P, Hildebrandt B, et al. Impact of overall treatment time on local control of anal cancer treated with radiochemotherapy. *Oncology.* 2003;65:14-22.
47. Roohipour R, Patil S, Goodman KA, et al. Squamous-cell carcinoma of the anal canal: predictors of treatment outcome. *Diseases of the Colon & Rectum.* 2008;51:147-153.
48. de Bree E, van Ruth S, Dewit LG, Zoetmulder FA. High risk of colostomy with primary radiotherapy for anal cancer. *Ann Surg Oncol.* 2007;14:100-108.
49. Baxter NN, Habermann EB, Tepper JE, et al. Risk of pelvic fracture in older women following pelvic irradiation. *JAMA.* 2005;294:2587-2593.
50. Lin A, Ben-Josef E. Intensity-modulated radiation therapy for the treatment of anal cancer. *Clin Colorectal Cancer.* 2007;6:716-719.
51. Salama JK, Mell LK, Schomas DA, et al. Concurrent chemotherapy and intensity-modulated radiation therapy for anal canal cancer patients: a multicenter experience. *J Clin Oncol.* 2007;25:4581-4586.
52. Milano MT, Jani AB, Farrey KJ, et al. Intensity-modulated radiation therapy (IMRT) in the treatment of anal cancer: toxicity and clinical outcome. *Int J Radiat Oncol Biol Phys.* 2005;63:354-361.
53. Chen Y-J, Liu A, Tsai PT, et al. Organ sparing by conformal avoidance intensity-modulated radiation therapy for anal cancer: dosimetric evaluation of coverage of pelvis and inguinal/femoral nodes. *Int J Rad Oncol Biol Phys.* 2005;63:274-281.
54. Myerson RJ, Garofolo MC, Naqa IE, et al. Elective clinical target volumes for conformal therapy in anorectal cancer: An Radiation Therapy Oncology Group Consensus Panel Contouring Atlas. *Int J Radiat Oncol Biol Phys.* 2008;74:824-830.
55. Hoffman R, Welton ML, Klencke B, Weinberg V, Krieg R. The significance of pretreatment CD4 count on the outcome and treatment tolerance of HIV-positive patients with anal cancer. *Int J Radiat Oncol Biol Phys.* 1999;44:127-131.
56. Fraunholz I, Weiss C, Eberlein K, et al. Concurrent chemoradiotherapy with 5-fluorouracil and mitomycin C for invasive anal carcinoma in human immunodeficiency virus-positive patients receiving highly active antiretroviral therapy. *Int J Radiat Oncol Biol Phys.* 2009; Sep 8 [Epub ahead of print].
57. Chiao EY, Giordano TP, Richardson P, El-Serg HB. Human immunodeficiency virus-associated squamous cell cancer of the anus:

epidemiology and outcomes in the highly active antiretroviral therapy era. *J Clin Oncol.* 2008;26:474-479.

58. Seo Y, Kinsella MT, Reynolds HL, et al. Outcomes of chemoradiotherapy with 5-fluorouracil and mitomycin C for anal cancer in immunocompetent versus immunodeficient patients. *Int J Radiat Oncol Biol Phys.* 2009 Feb 7

59. Oehler-Janne C, Huguet F, Provencher S, et al. HIV-specific differences in outcome of squamous cell carcinoma of the anal canal: a multicentric cohort study of HIV-positive patients receiving highly active antiretroviral therapy. *J Clin Oncol.* 2008;26:2550-2557.

60. Klencke BJ, Palefsky JM. Anal cancer: an HIV-associated cancer. *Hematol Oncol Clin North Am.* 2003;17:859-872.

61. Faivre C, Rougier P, Ducreux M, et al. 5-Fluorouracil and cisplatin combination chemotherapy for metastatic squamous-cell anal cancer. *Bull Cancer.* 1999;86:861-865.

62. Nigro ND. An evaluation of combined therapy for squamous cell cancer of the anal canal. *Dis Colon Rectum.* 1984;27:763-766.

63. Cummings BJ, Keane TJ, O'Sullivan B, Wong CS, Catton CN. Epidermoid anal cancer: treatment by radiation alone or by radiation and 5-fluorouracil with and without mitomycin C. *Int J Radiat Oncol Biol Phys.* 1991;21:1115-1125.

64. Mullen JT, Rodriguez-Bigas MA, Chang GJ, et al. Results of surgical salvage after failed chemoradiation therapy for epidermoid carcinoma of the anal canal. *Ann Surg Oncol.* 2007;14:478-483.

65. Renehan AG, Saunders MP, Schofield PF, O'Dwyer ST. Patterns of local disease failure and outcome after salvage surgery in patients with anal cancer. *Br J Surg.* 2005;92:605-614.

66. Das P, Bhatia S, Eng C, et al. Predictors and patterns of recurrence after definitive chemoradiation for anal cancer. *Int J Radiat Oncol Biol Phys.* 2007;68:794-800.

67. Nilsson PJ, Svensson C, Goldman S, Glimelius B. Salvage abdominoperineal resection in anal epidermoid cancer. *Br J Surg.* 2002;89:1425-1429.

68. Allal AS, Laurencet FM, Reymond MA, Kurtz JM, Marti MC. Effectiveness of surgical salvage therapy for patients with locally uncontrolled anal carcinoma after sphincter-conserving treatment. *Cancer.* 1999;86:405-409.

69. Ellenhorn JD, Enker WE, Quan SH. Salvage abdominoperineal resection following combined chemotherapy and radiotherapy for epidermoid carcinoma of the anus. *Ann Surg Oncol.* 1994;1:105-110.

70. Schiller DE, Cummings BJ, Rai S, et al. Outcomes of salvage surgery for squamous cell carcinoma of the anal canal. *Ann Surg Oncol.* 2007;14:2780-2789.

71. Chessin DB, Hartley J, Cohen AM, et al. Rectus flap reconstruction decreases perineal wound complications after pelvic chemoradiation and surgery: a cohort study. *Ann Surg Oncol.* 2005;12:104-110.

72. Cummings BJ, Keane TJ, O'Sullivan B, et al. Metastatic anal cancer: the search for a cure. *Onkologie.* 2006;29:5-6.

73. Ajani JA, Carrasco CH, Jackson DE, Wallace S. Combination of cisplatin plus fluoropyrimidine chemotherapy effective against liver metastases from carcinoma of the anal canal. *Am J Med.* 1989;87:221-224.

74. Jaiyesimi IA, Pazdur R. Cisplatin and 5-fluorouracil as salvage therapy for recurrent metastatic squamous cell carcinoma of the anal canal. *Am J Clin Oncol.* 1993;16:536-540.